

BONE ANATOMY

Diaphysis: long shaft of bone

Epiphysis: ends of bone

Epiphyseal plate: growth plate

Metaphysis: b/w epiphysis and diaphysis

Articular cartilage: covers epiphysis

Periosteum: bone covering (pain sensitive)

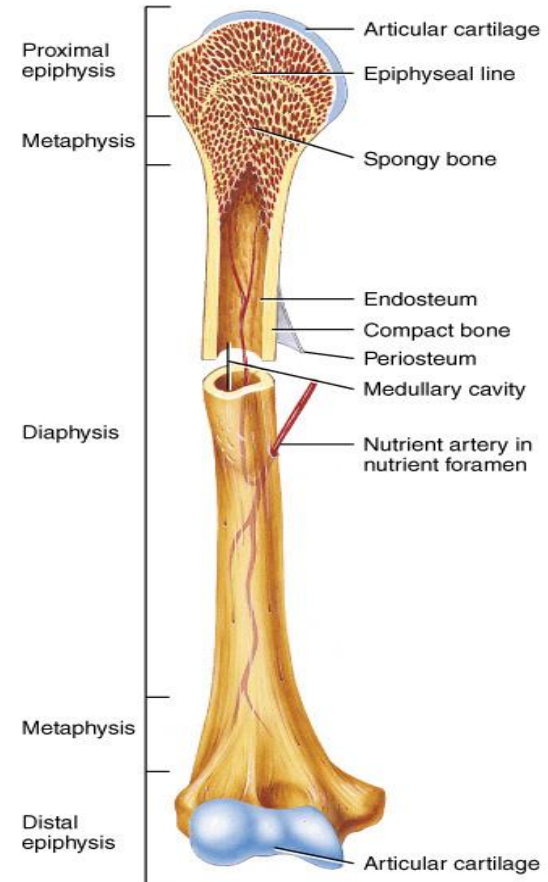
Sharpey's fibers: periosteum attaches to underlying bone

Medullary cavity: Hollow chamber in bone

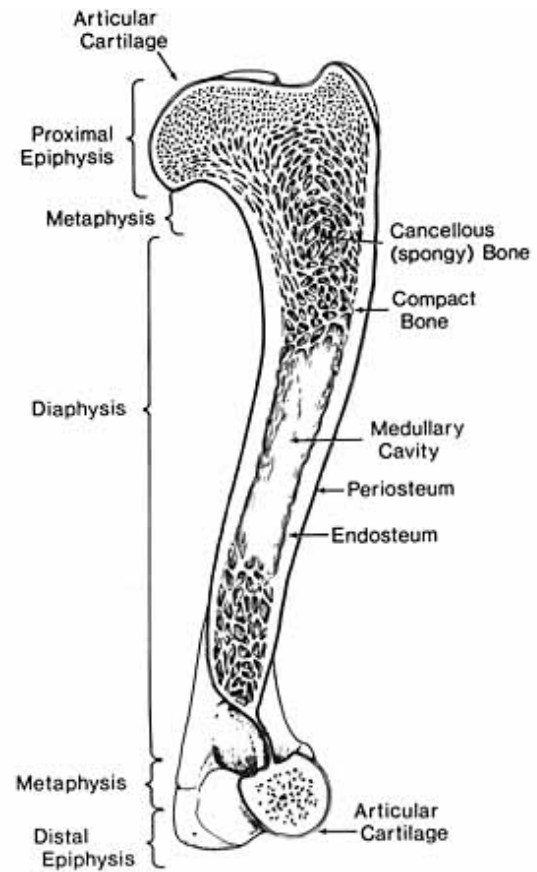
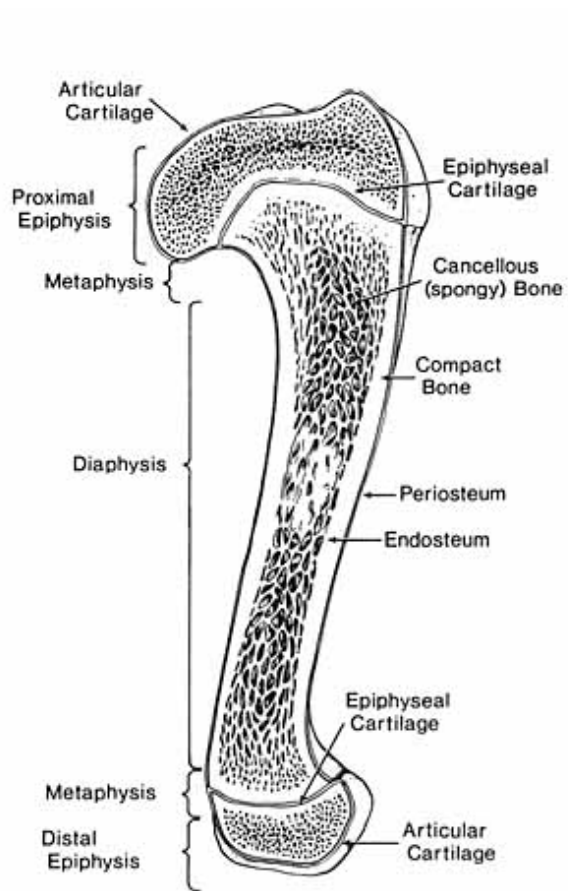
- red marrow produces blood cells

- yellow marrow is adipose

Endosteum: thin layer lining the medullary cavity



(a) Partially sectioned humerus (arm bone)



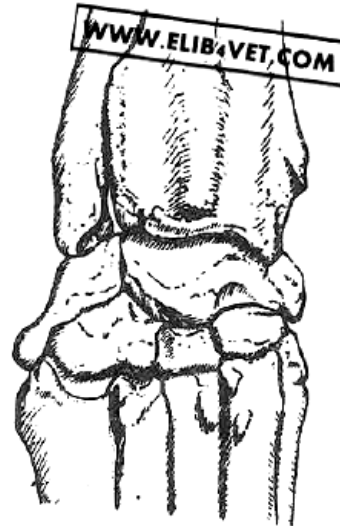
انواع استخوان از نظر شکل

1-Long Bone ■

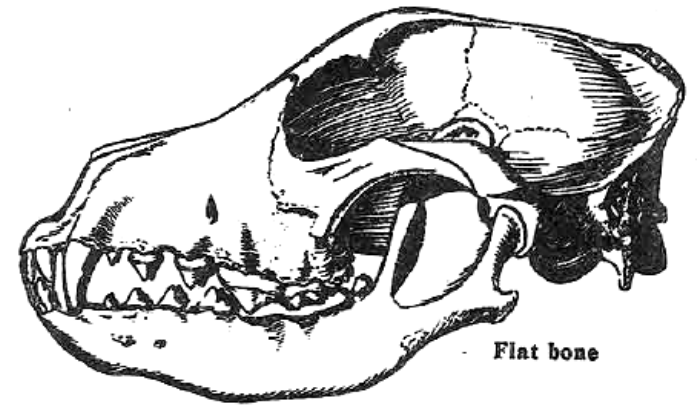
2-Short Bone ■

3-Flat Bone ■

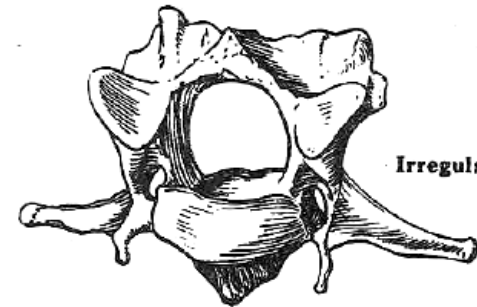
4-Irregular Bone ■



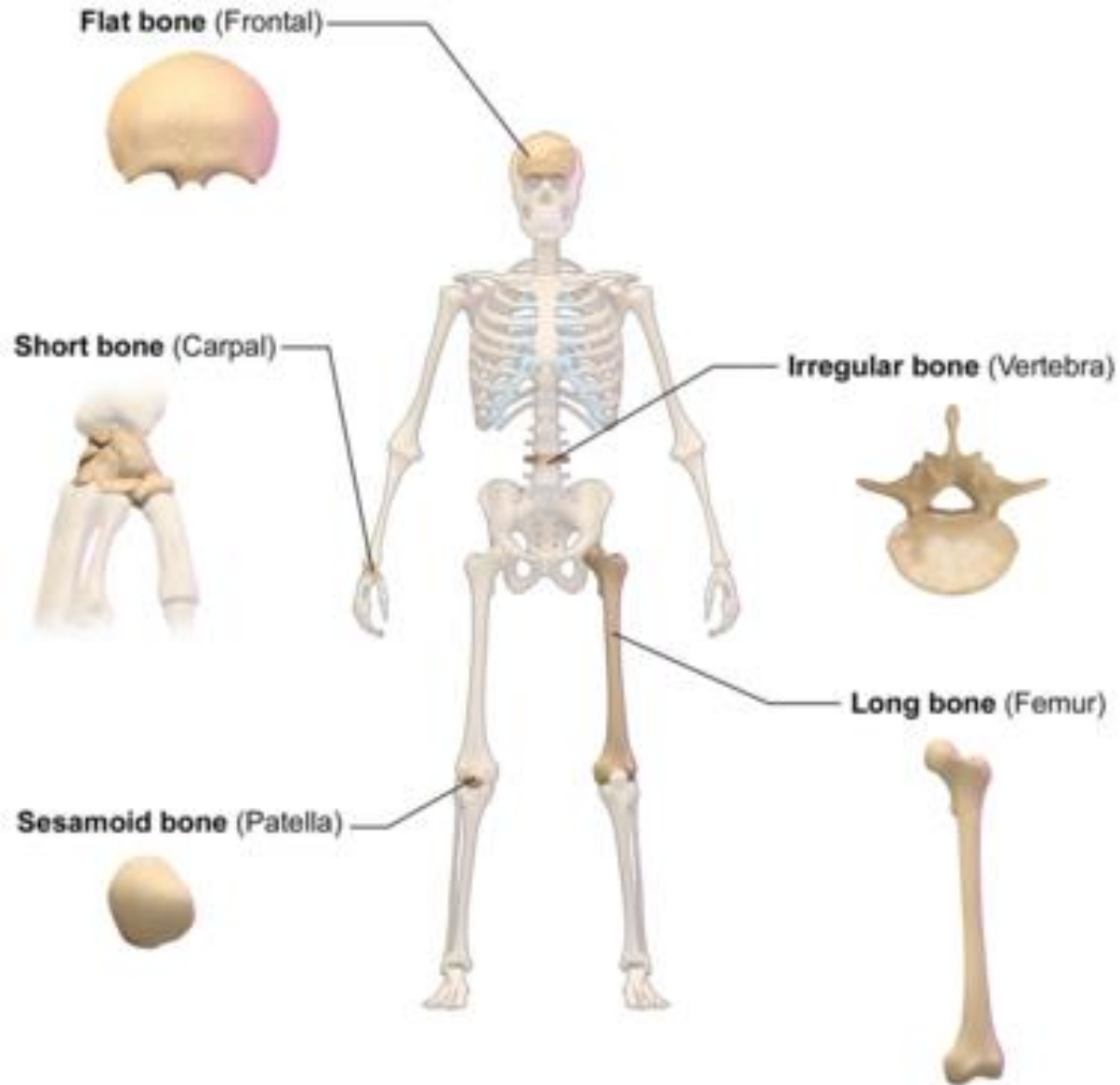
Short bone



Flat bone



Irregular bone



Classification of Bones by Shape

استخوان های بلند Long bones

BONE PROCESSES

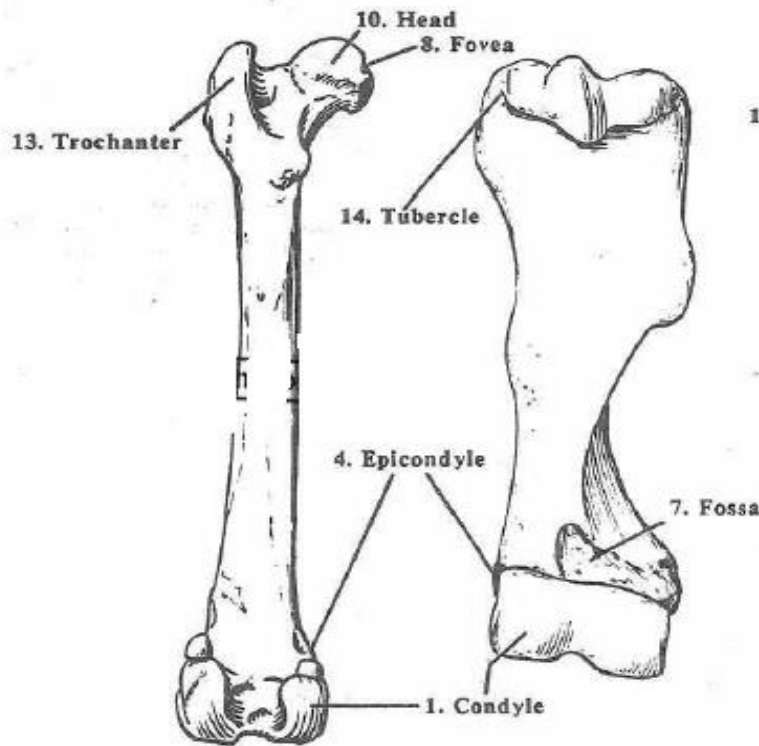


Fig. II-5 - Femur & Humerus

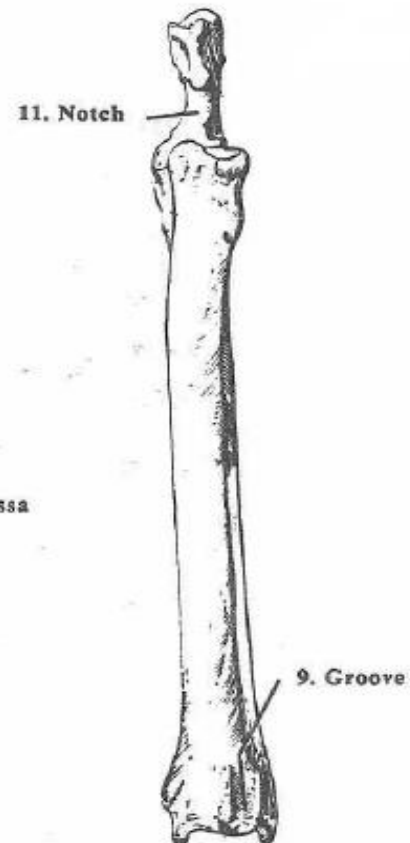


Fig. II-6 - Radius & Ulna

BONE ANATOMY

Diaphysis: long shaft of bone

Epiphysis: ends of bone

Epiphyseal plate: growth plate

Metaphysis: b/w epiphysis and diaphysis

Articular cartilage: covers epiphysis

Periosteum: bone covering (pain sensitive)

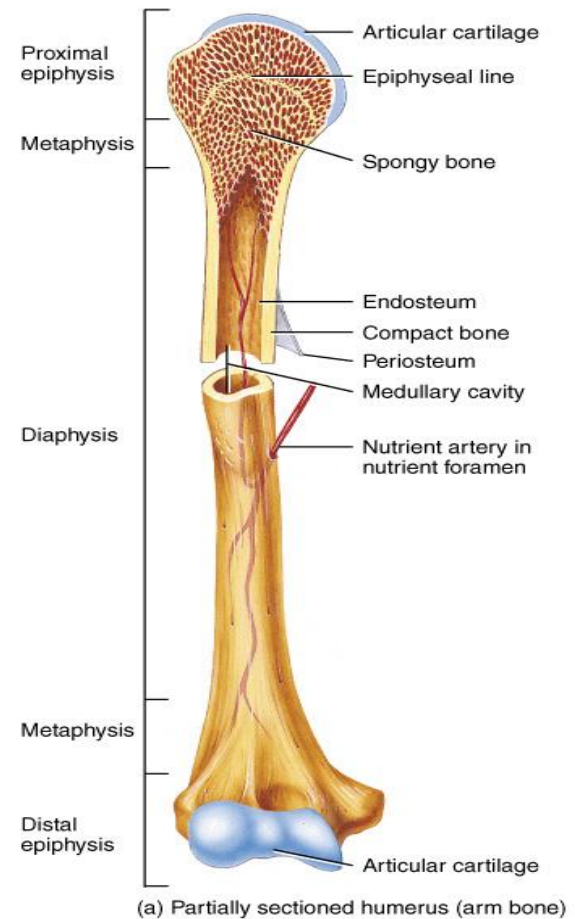
Sharpey's fibers: periosteum attaches to underlying bone

Medullary cavity: Hollow chamber in bone

- red marrow produces blood cells

- yellow marrow is adipose

Endosteum: thin layer lining the medullary cavity



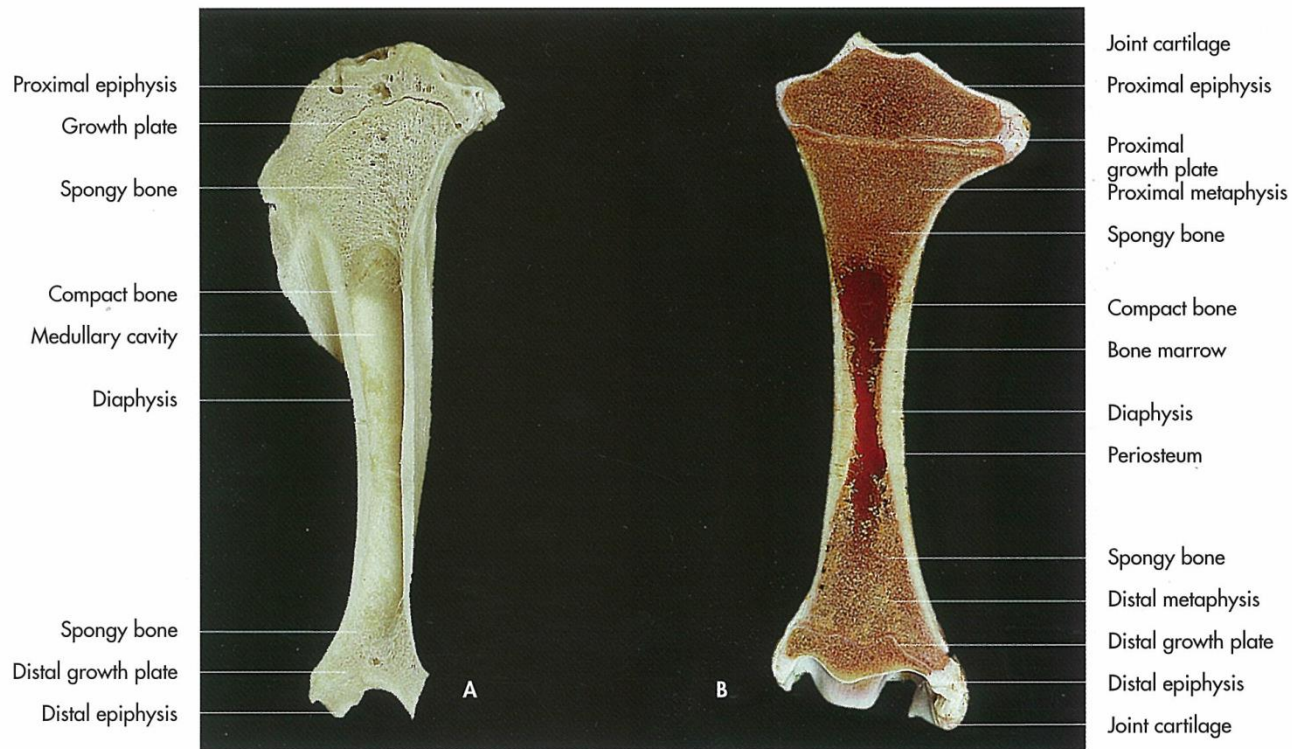
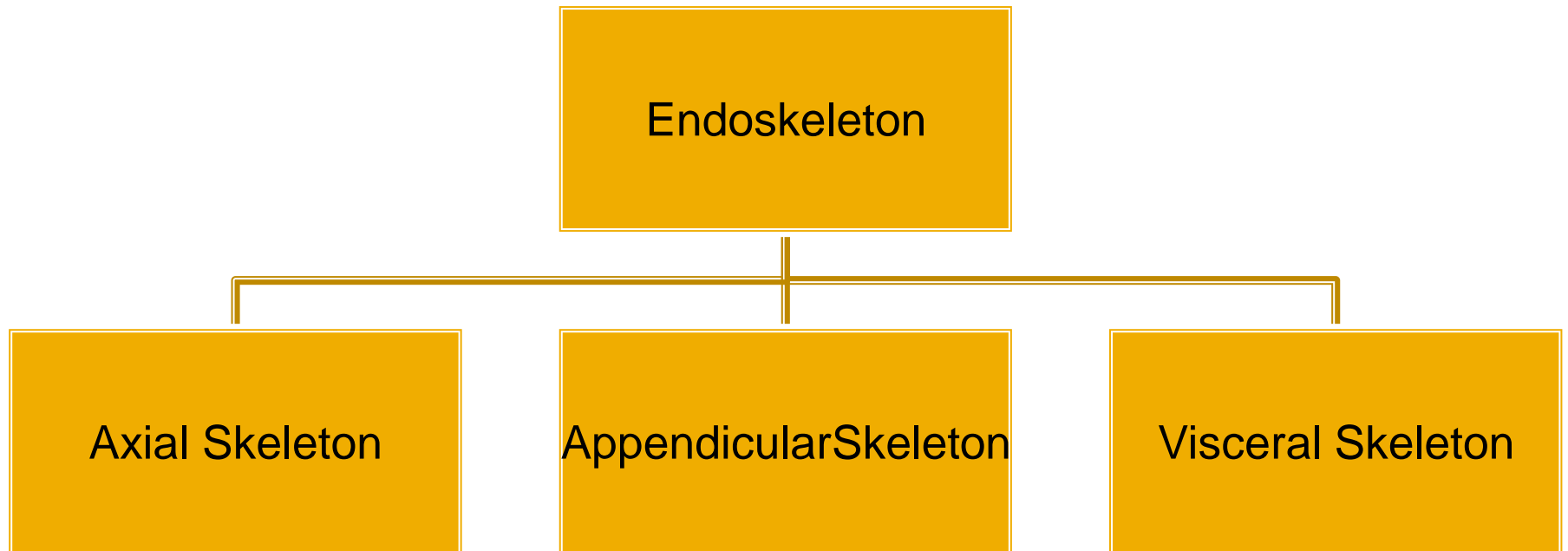


Fig. 0-3. Sagittal section of a long bone after maceration (A), sagittal section of a long bone in a fresh state with articular cartilage and red bone marrow (B).

Osteology



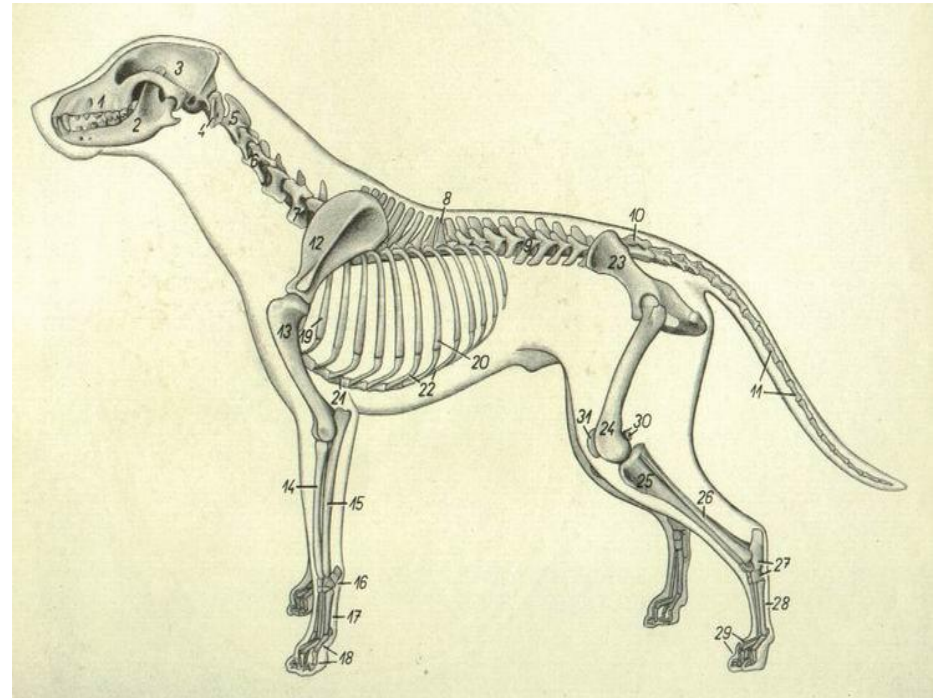
استخوان های Axial skeleton

محوری

Skull

Thorax

Vertebral
collumn



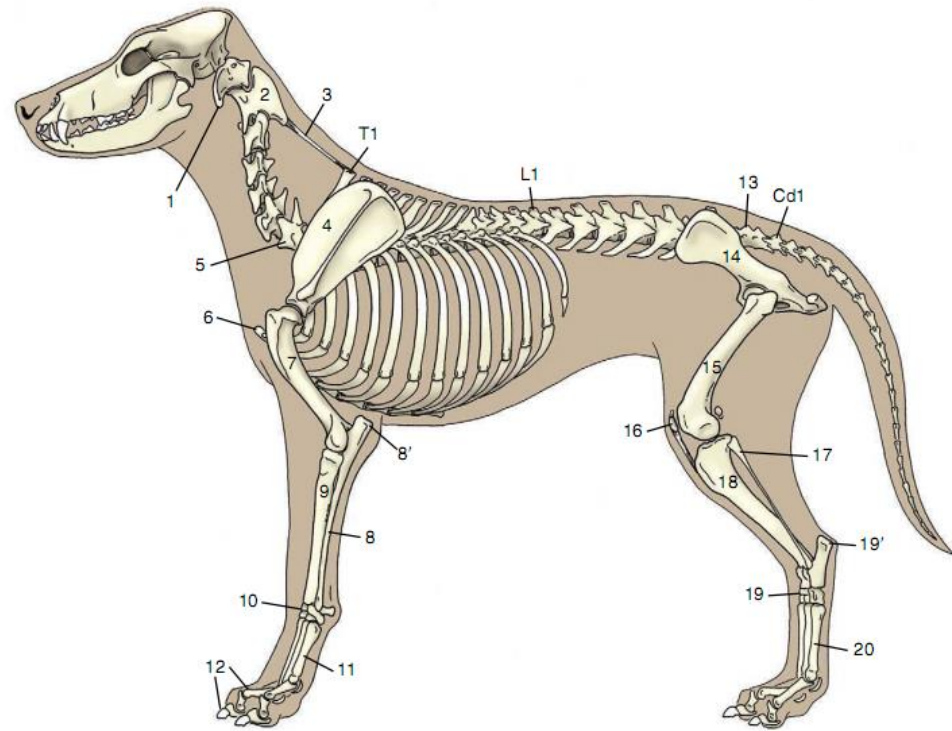


TABLE 4-1 Bones of Skeletal System

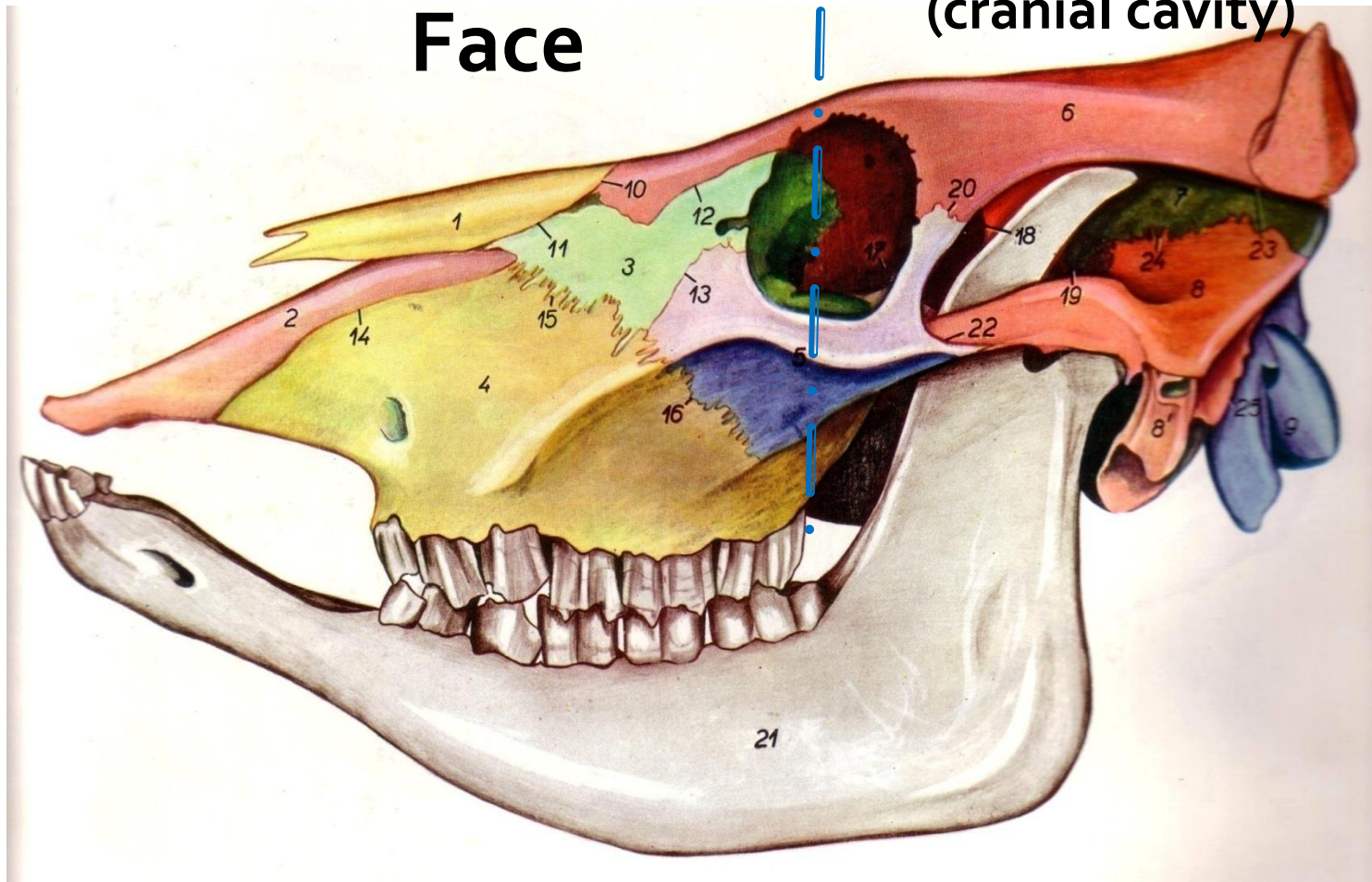
DIVISION	TOTAL AVERAGE NUMBER
Axial Skeleton	
Vertebral column	50
Skull and hyoid	50
Ribs and sternum	34
Appendicular Skeleton	
Thoracic limbs	90
Pelvic limbs	96
Heterotopic Skeleton	
Os penis	1
Total	321

Skull

صفحه عرضی
جدا کننده
صورت از حفره
سری

Face

Cranium
(cranial cavity)



Skull(Face)

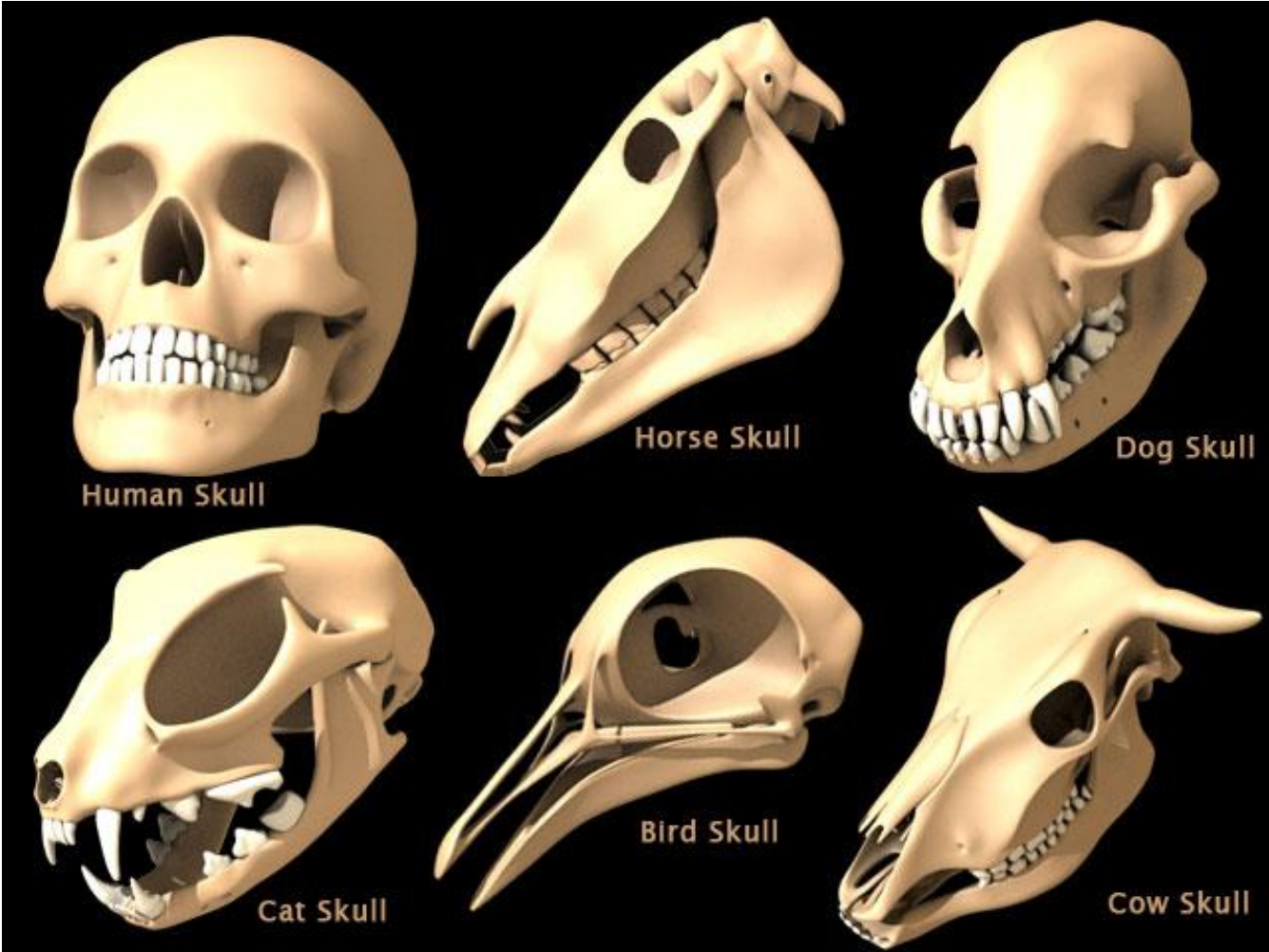


Maxilla
Incisive (Premaxilla)
Palatine
Pterygoid
Nasal
Lacrimal
Zygomatic
Vomer
Concha
Hyoid apparatus
Mandible

Skull(Cranium)



Occipital
Sphenoid
Temporal
Parietal
Inter-parietal
Frontal
Ethmoid



Human Skull

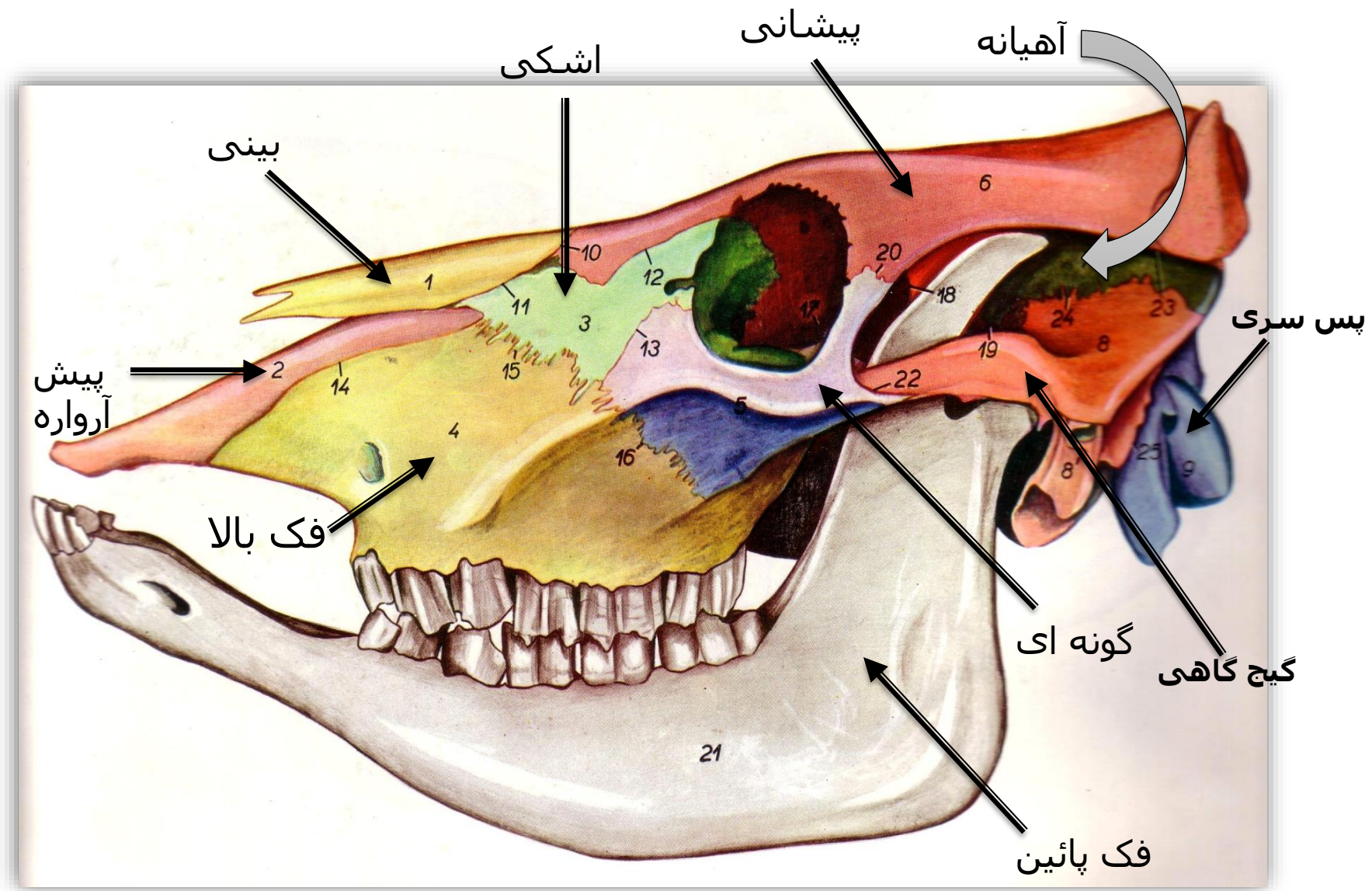
Horse Skull

Dog Skull

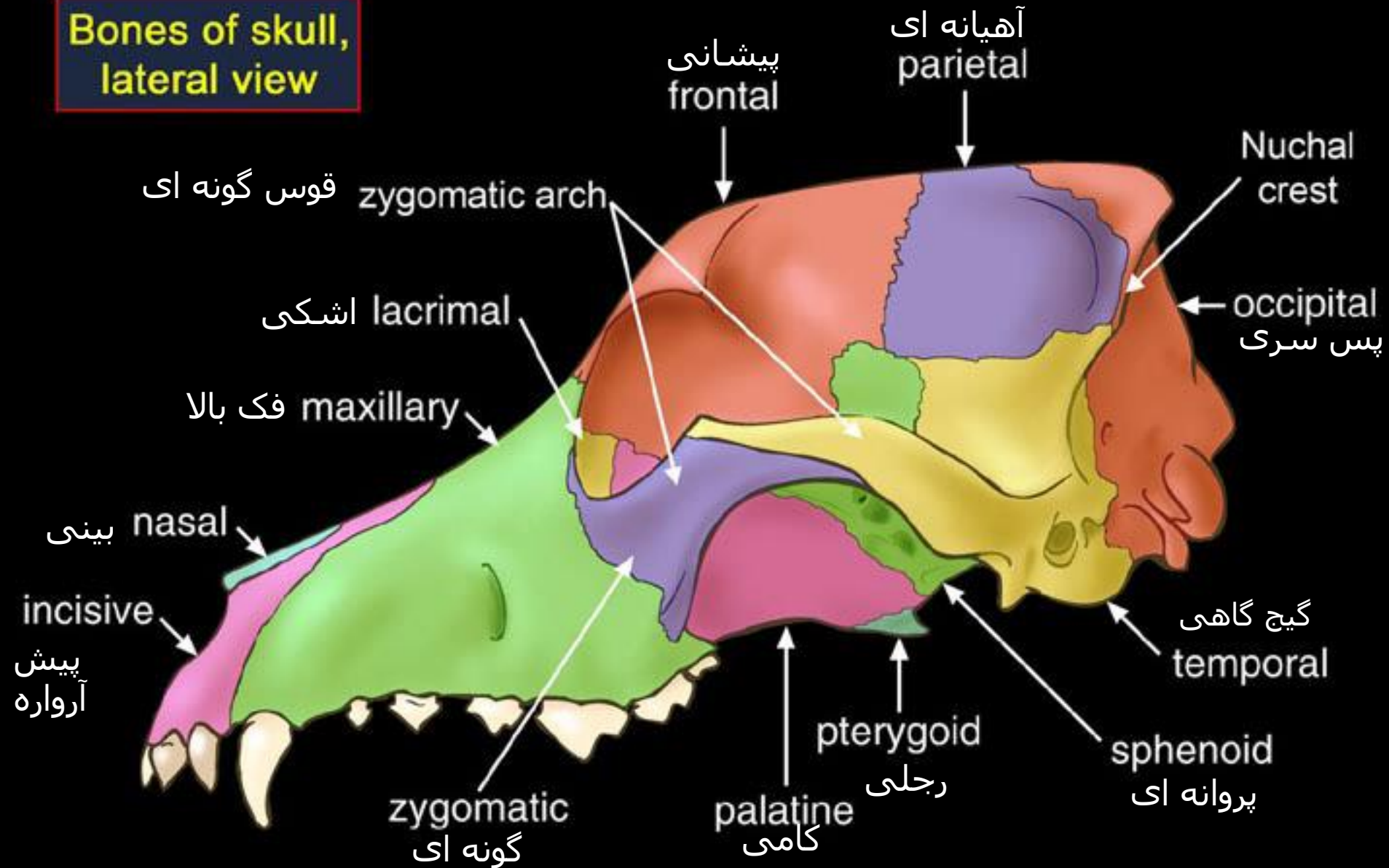
Cat Skull

Bird Skull

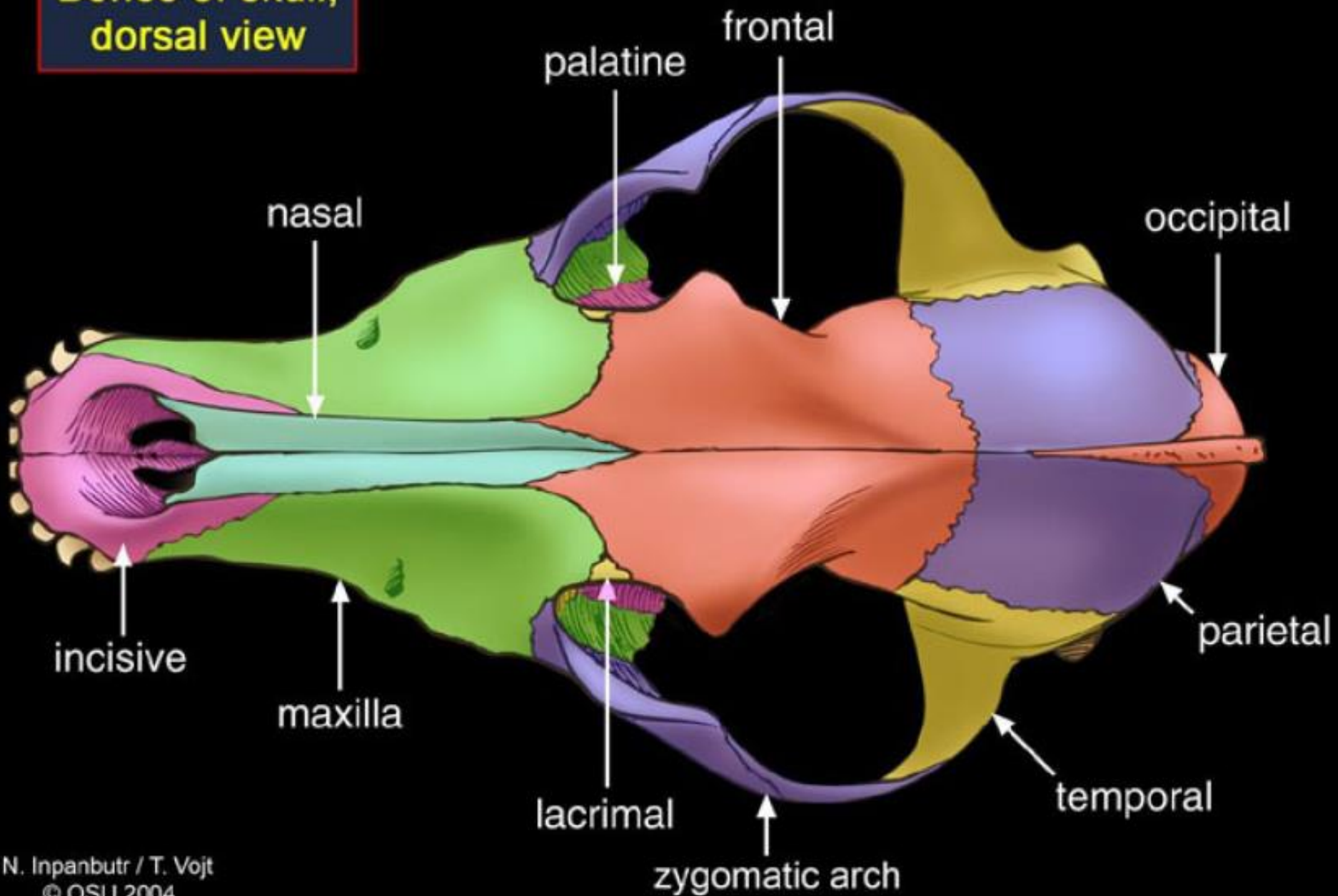
Cow Skull

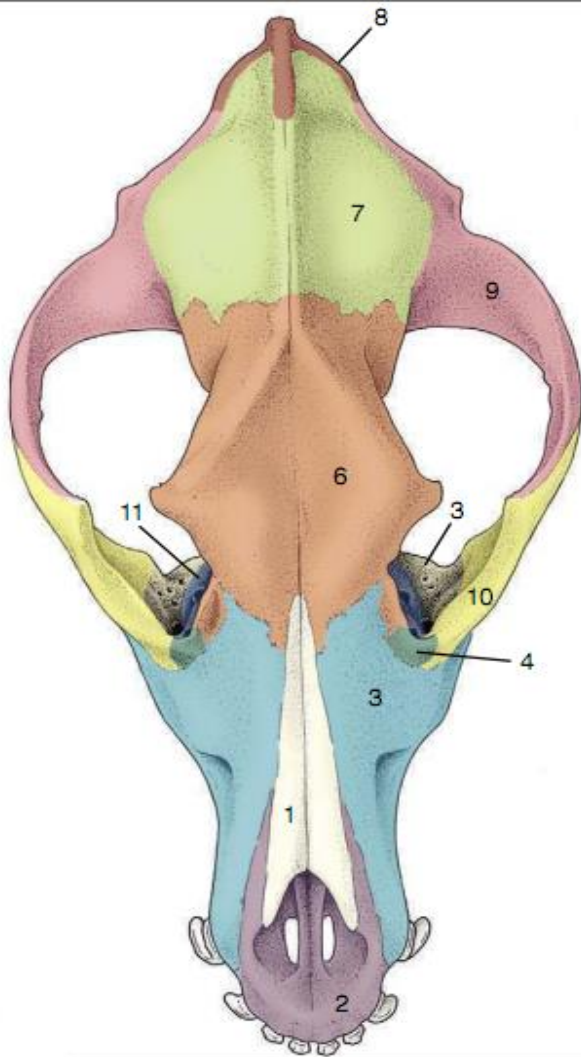


**Bones of skull,
lateral view**

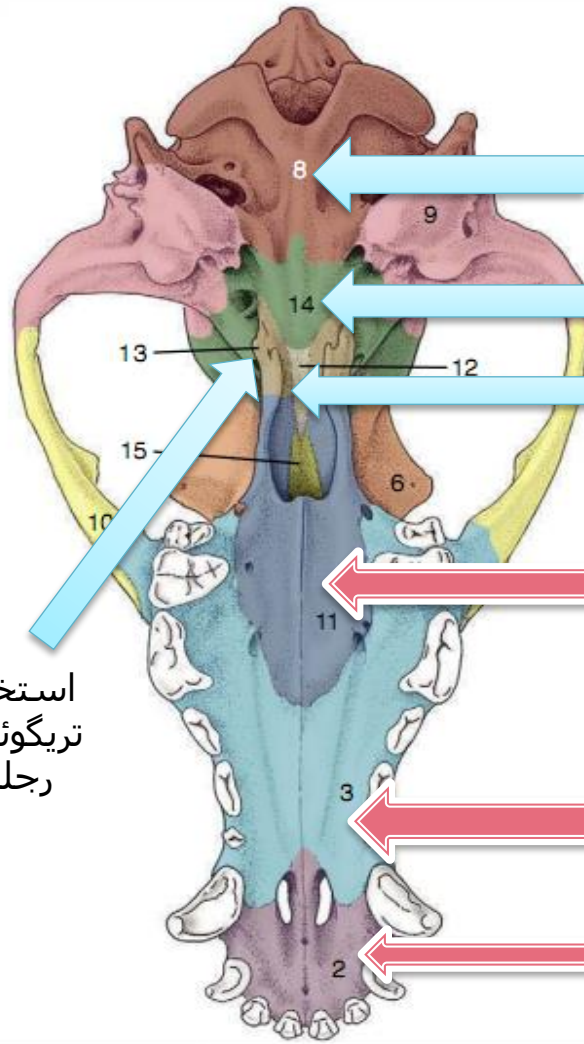


**Bones of skull,
dorsal view**





استخوان
تریگوئید یا
رجلی



قسمت قاعده ای
استخوان پس سری

استخوان پروانه ای
قاعده ای

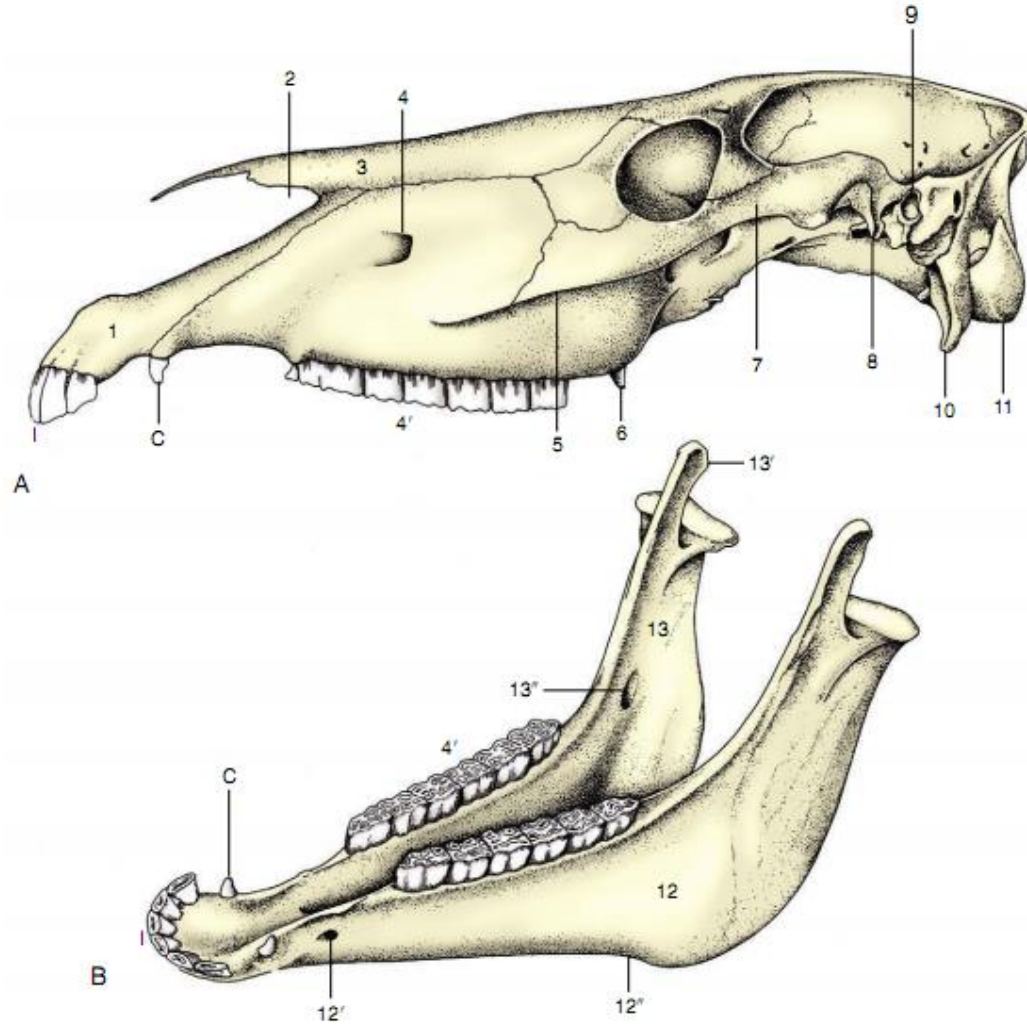
استخوان پیش
پروانه ای

استخوان کامی
(صفحه افقی)

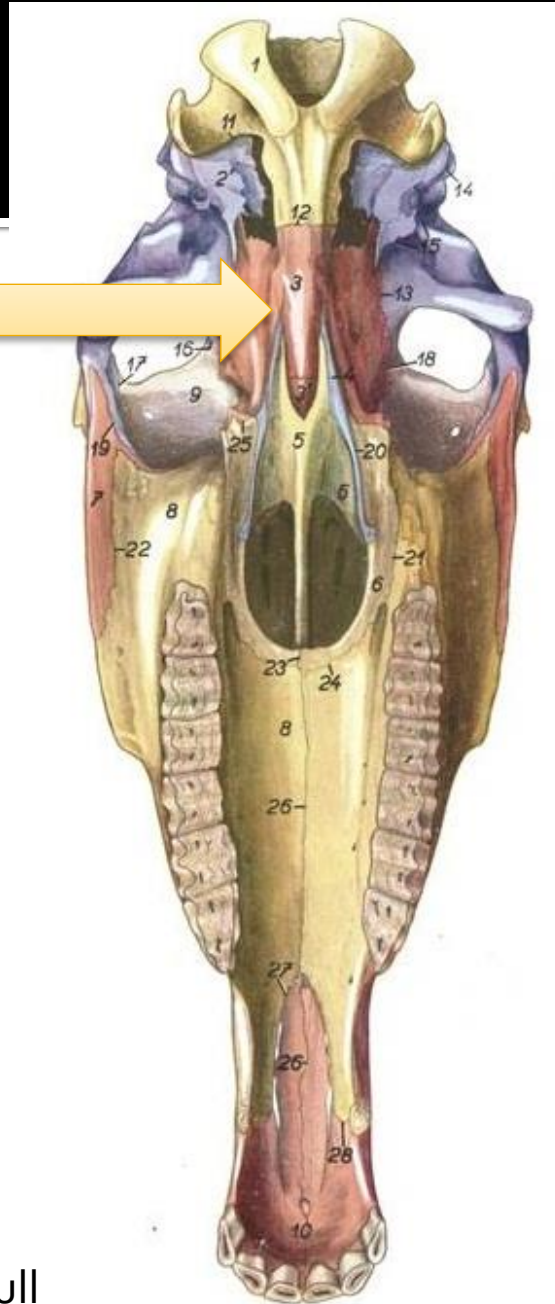

استخوان فک بالا

استخوان ثنا یا

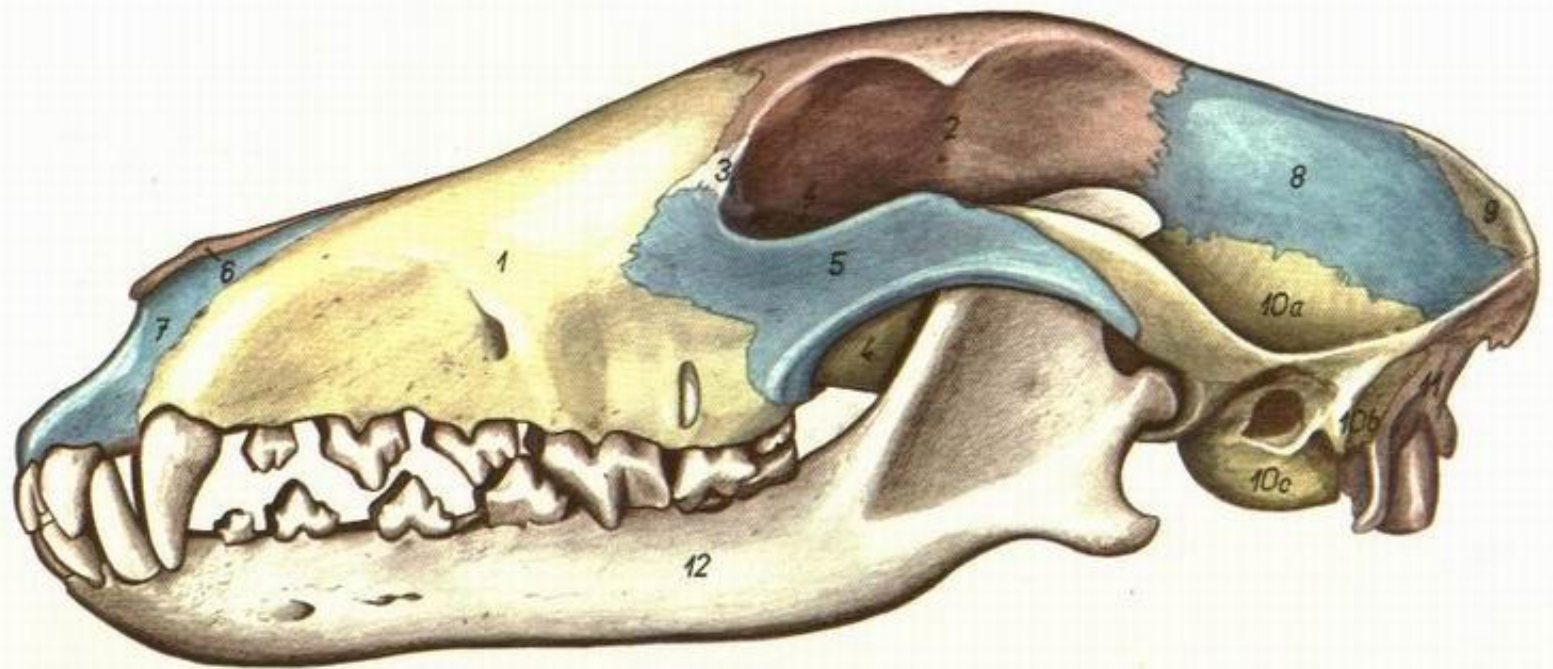
Tempomandibular Joint



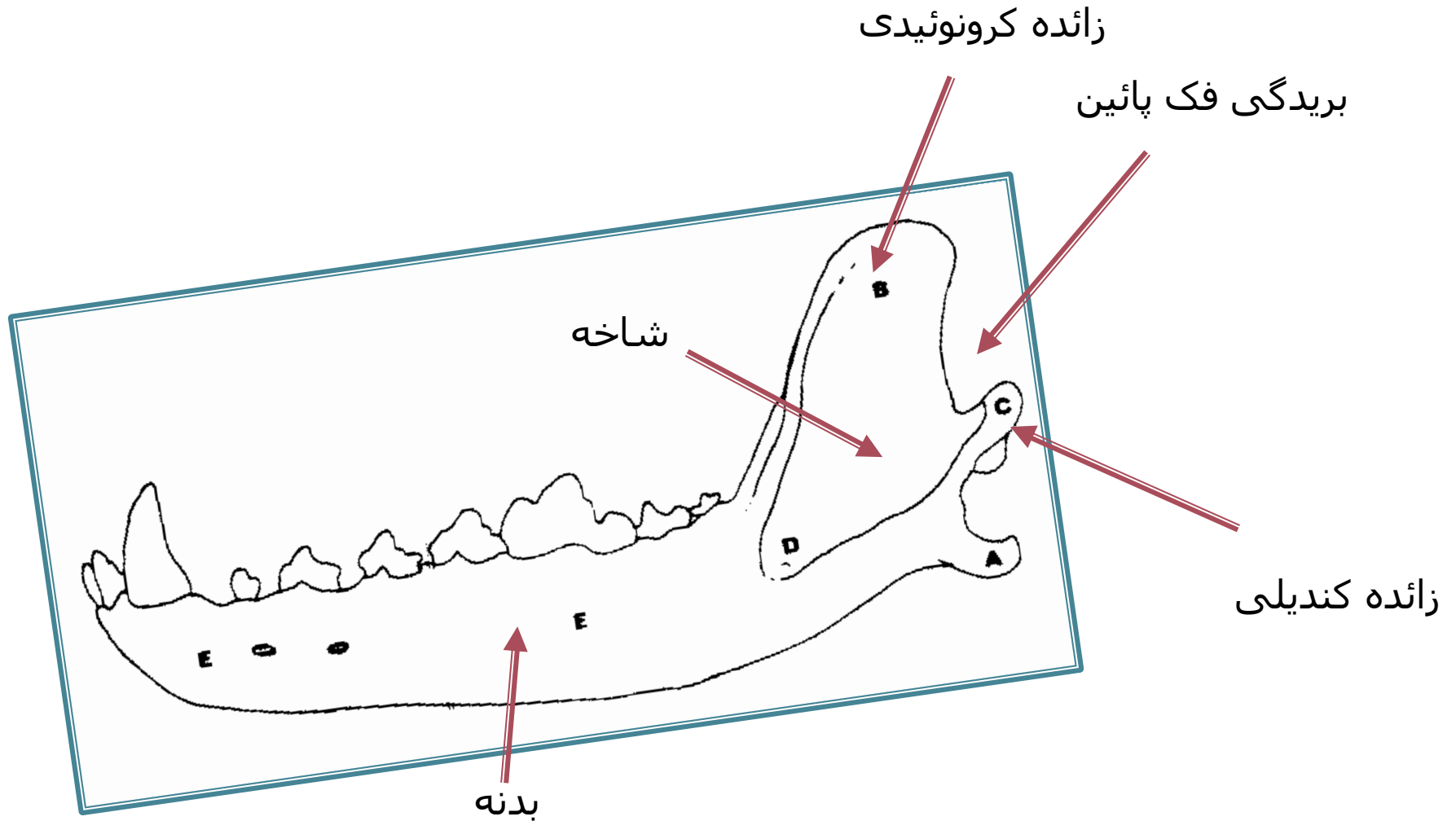
Sphenoid B.



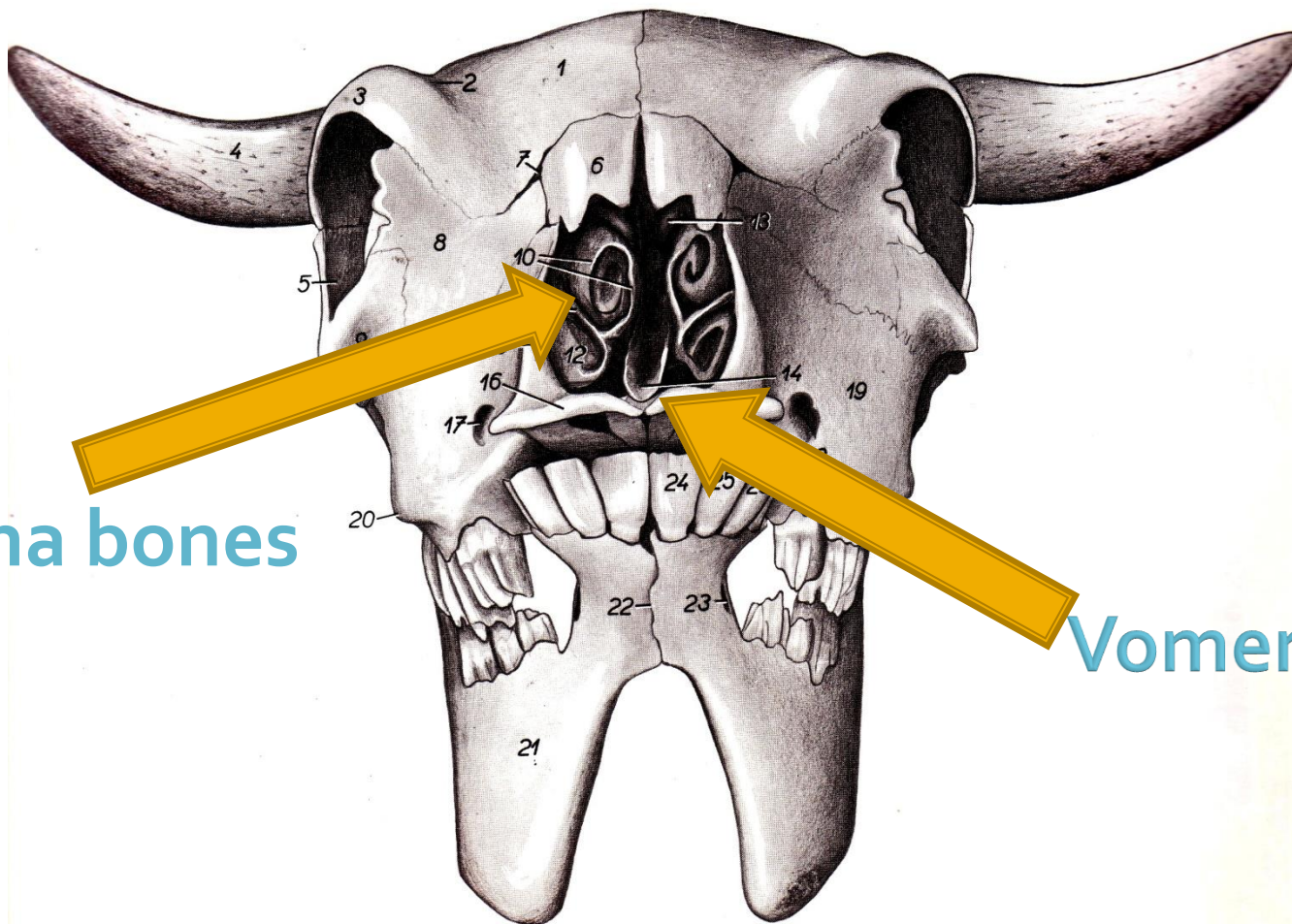
Ventral view of equine skull



استخوان فک پائین Mandible در سگ



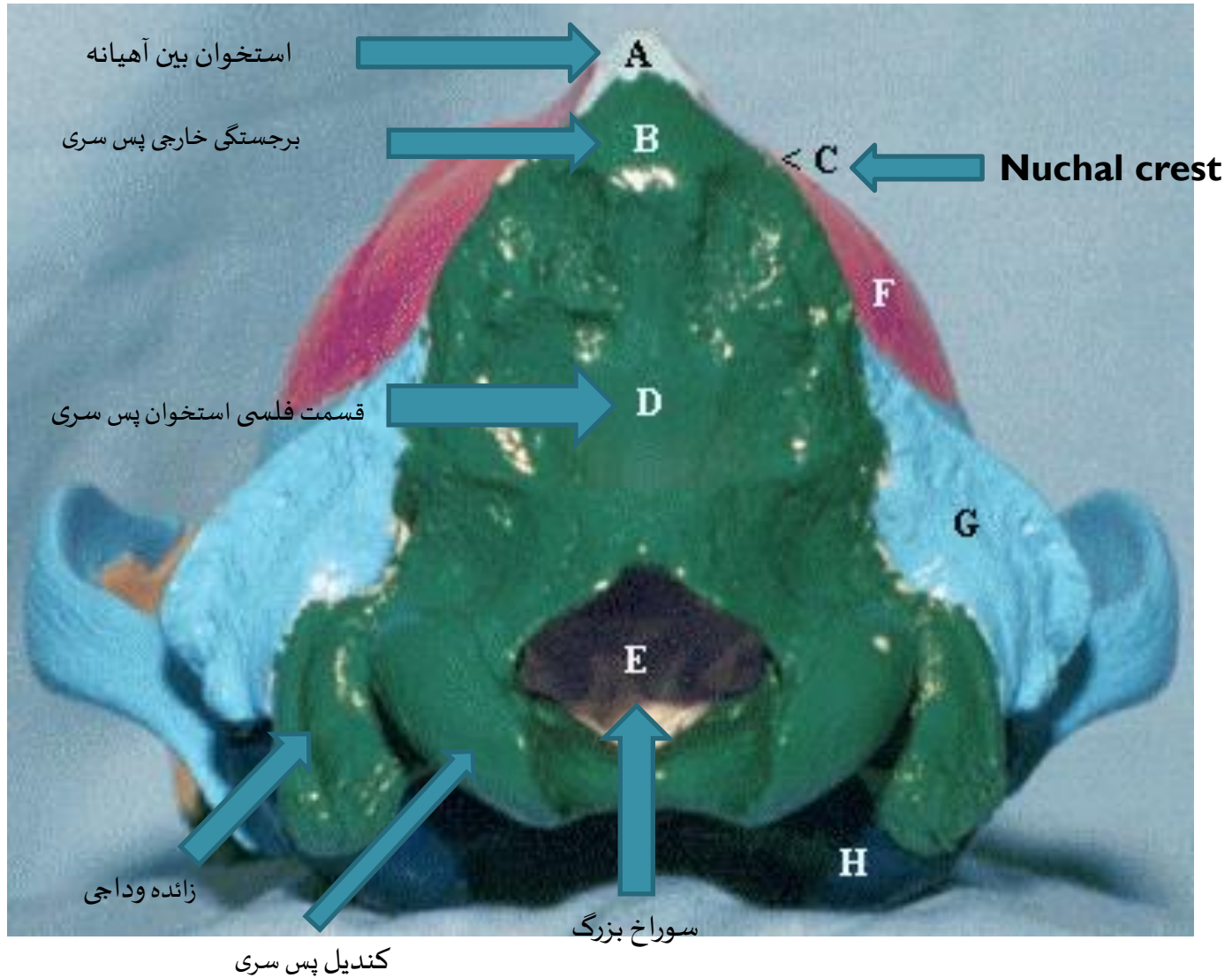
نمای جلویی جمجمه ی گاو



Concha bones

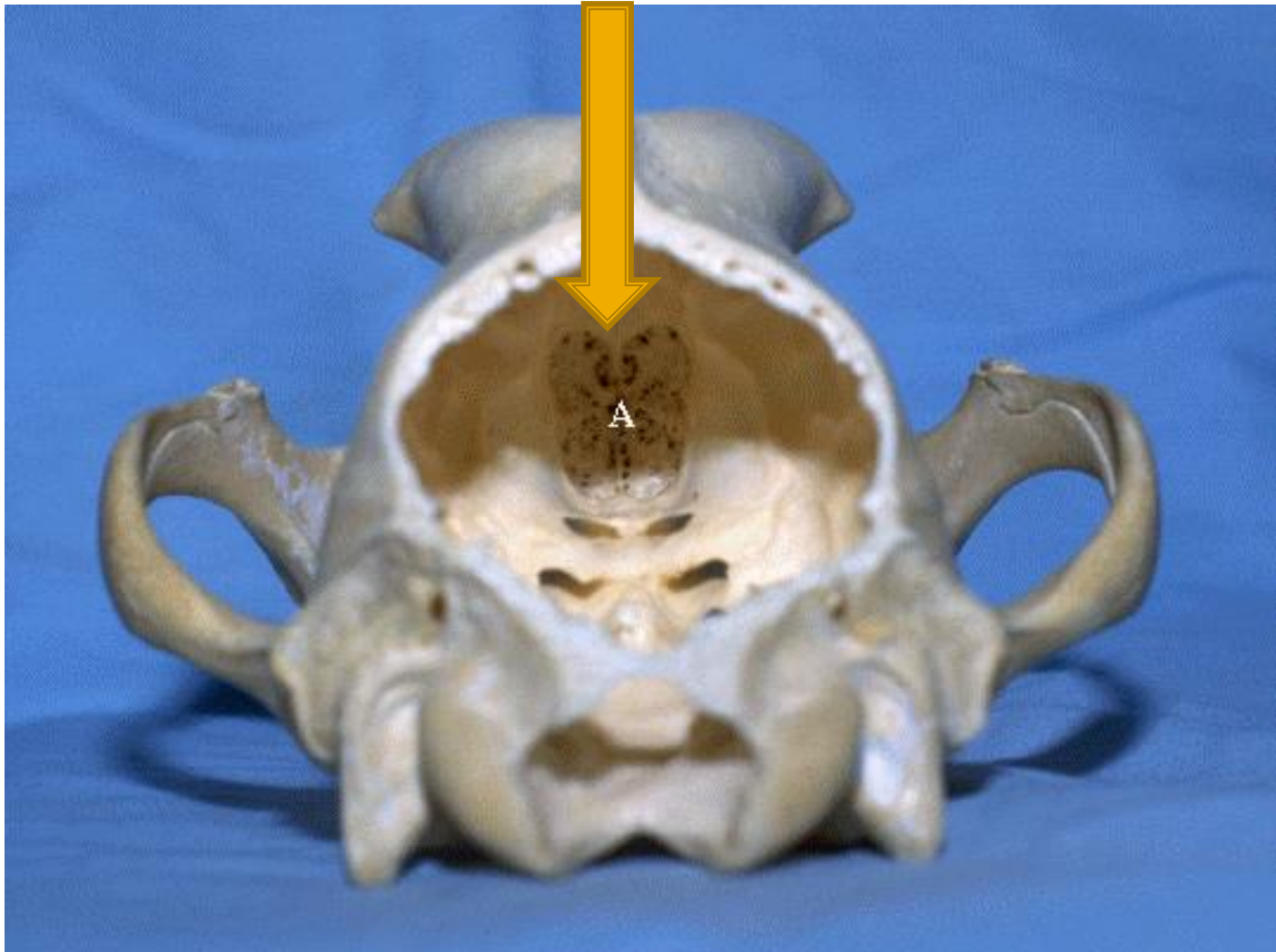
Vomer B.

نمای عقبی جمجمه سگ



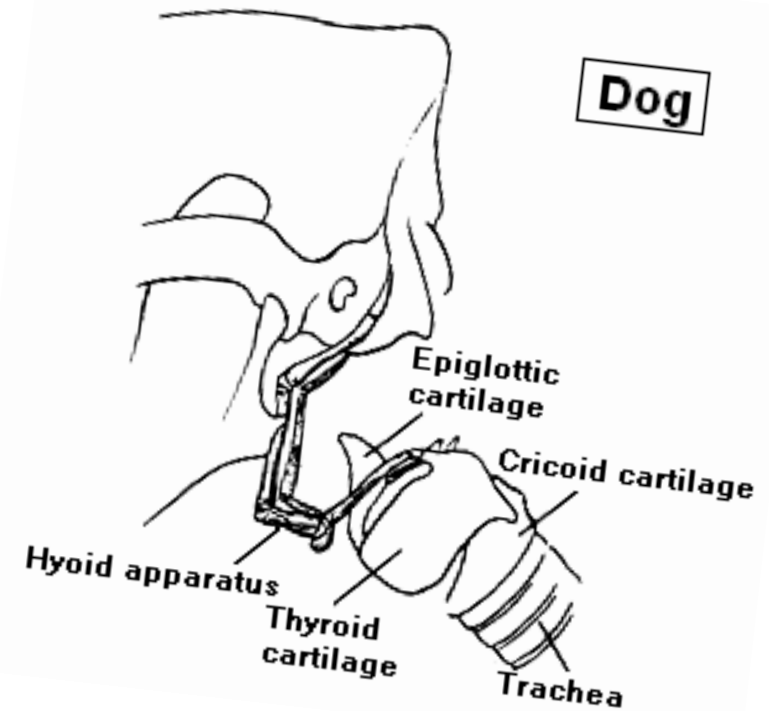
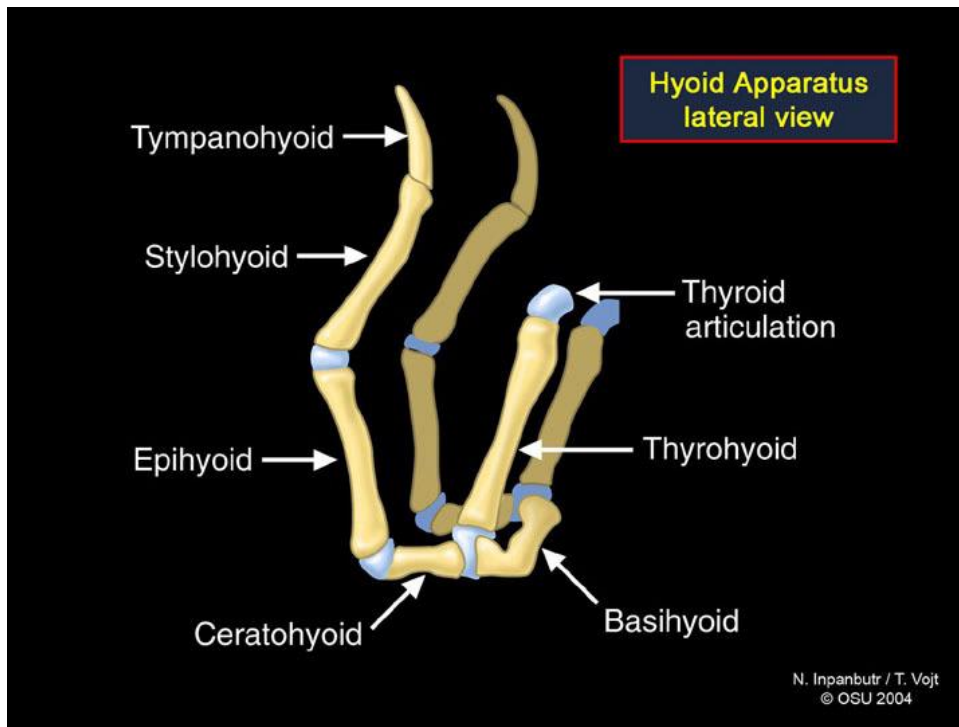
نمای عقبی جمجمه سگ

Ethmoidal b. / استخوان پرویزنی

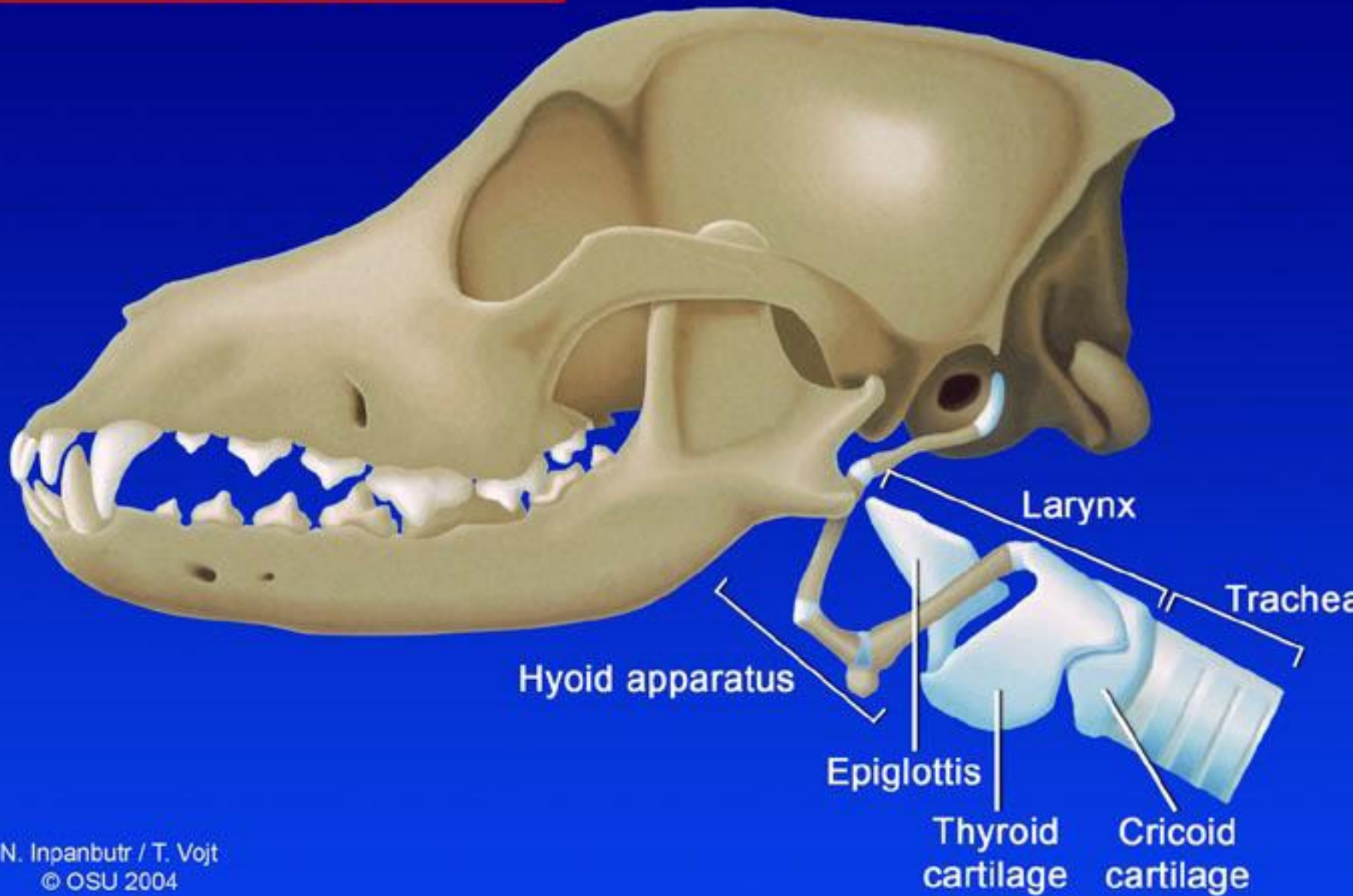


Hyoid apparatus

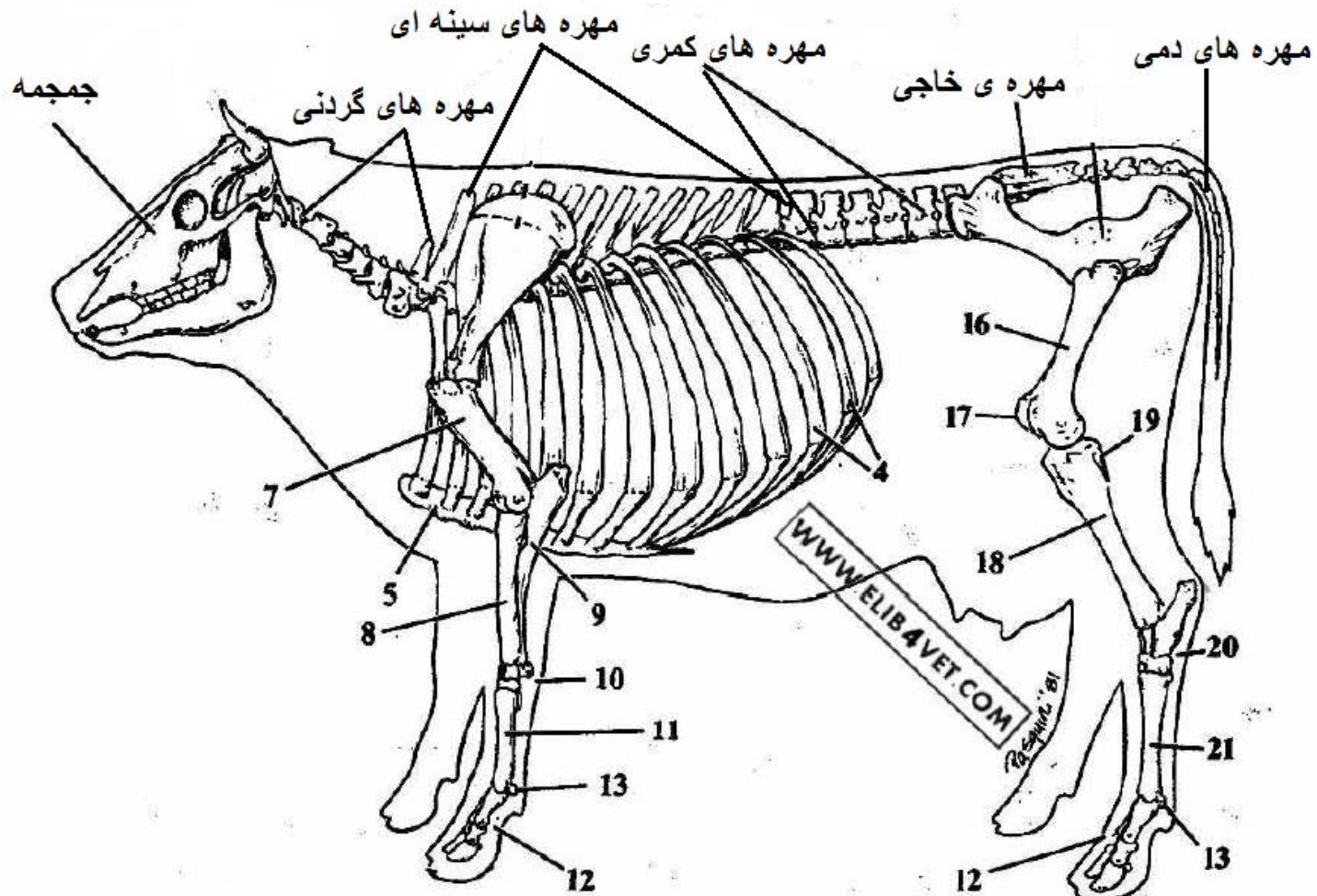
دستگاه لامی

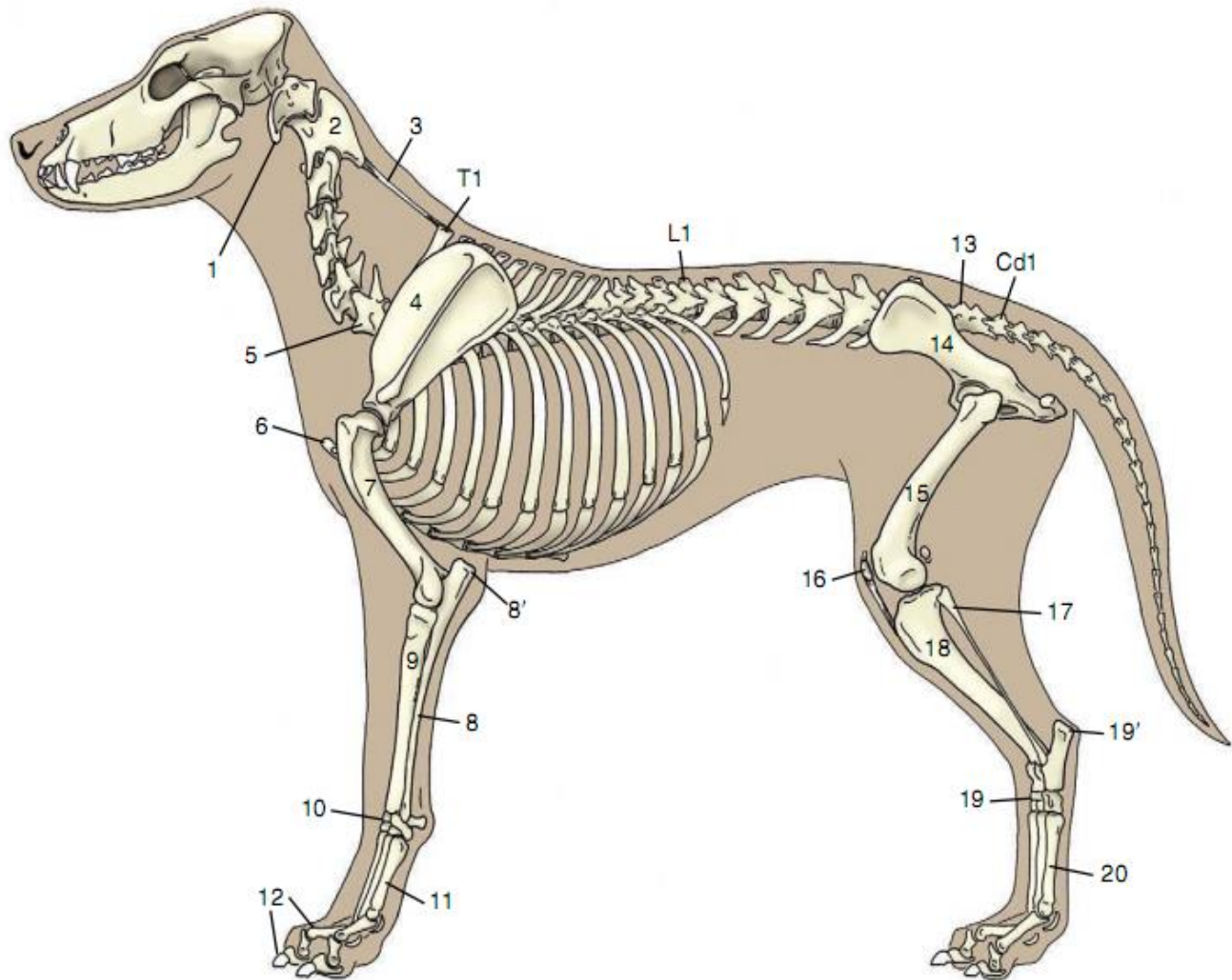


Hyoid Apparatus and larynx, lateral view

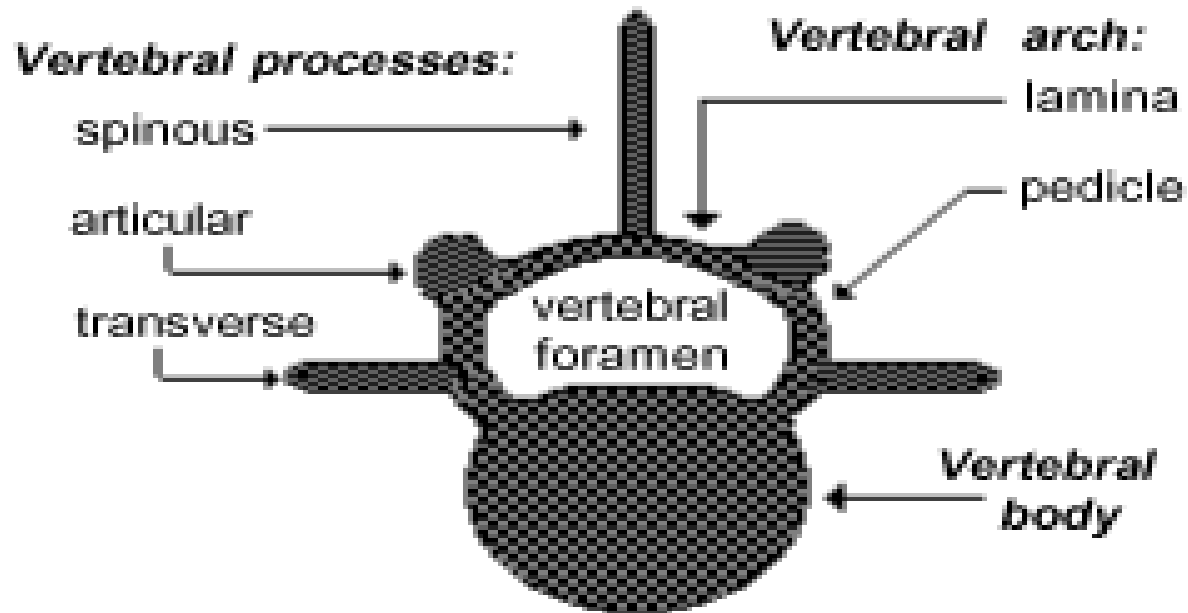


ستون مهره ها **Vertebral column**

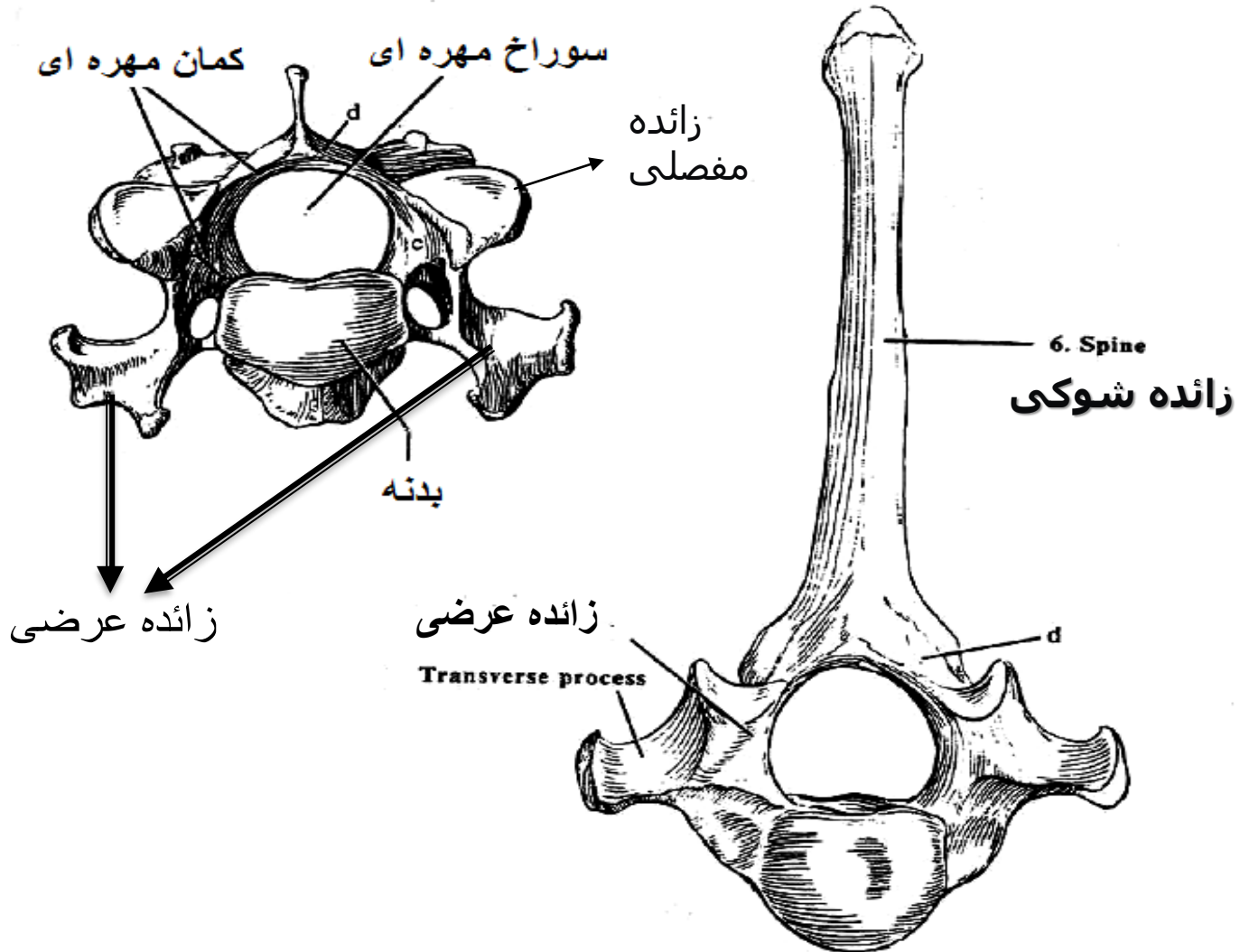




ویژگی های یک مهره نمونه



مهره نمونه



غضروف بین مهره ای

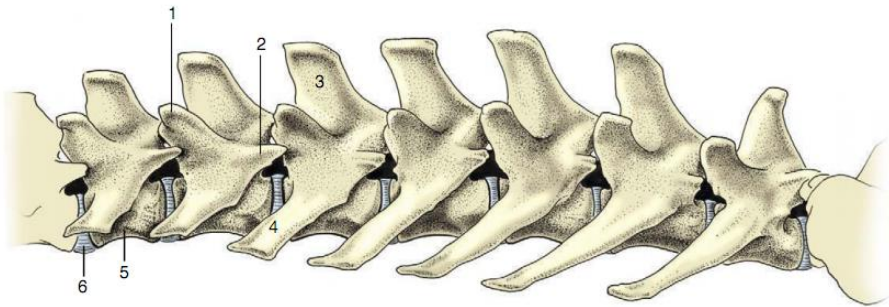


Figure 2-11 Lumbar vertebrae of the dog, left lateral view. 1, Mamillary process; 2, accessory process; 3, spinous process; 4, transverse process; 5, body; 6, intervertebral disk.

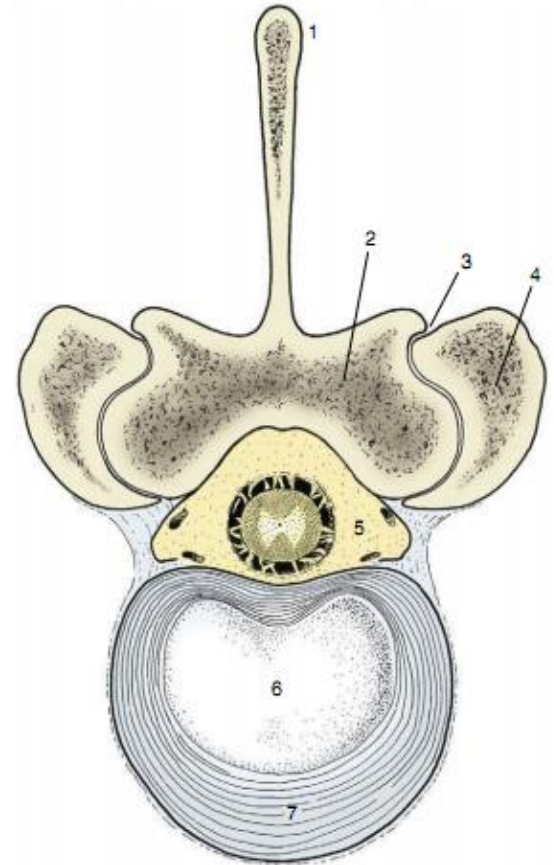
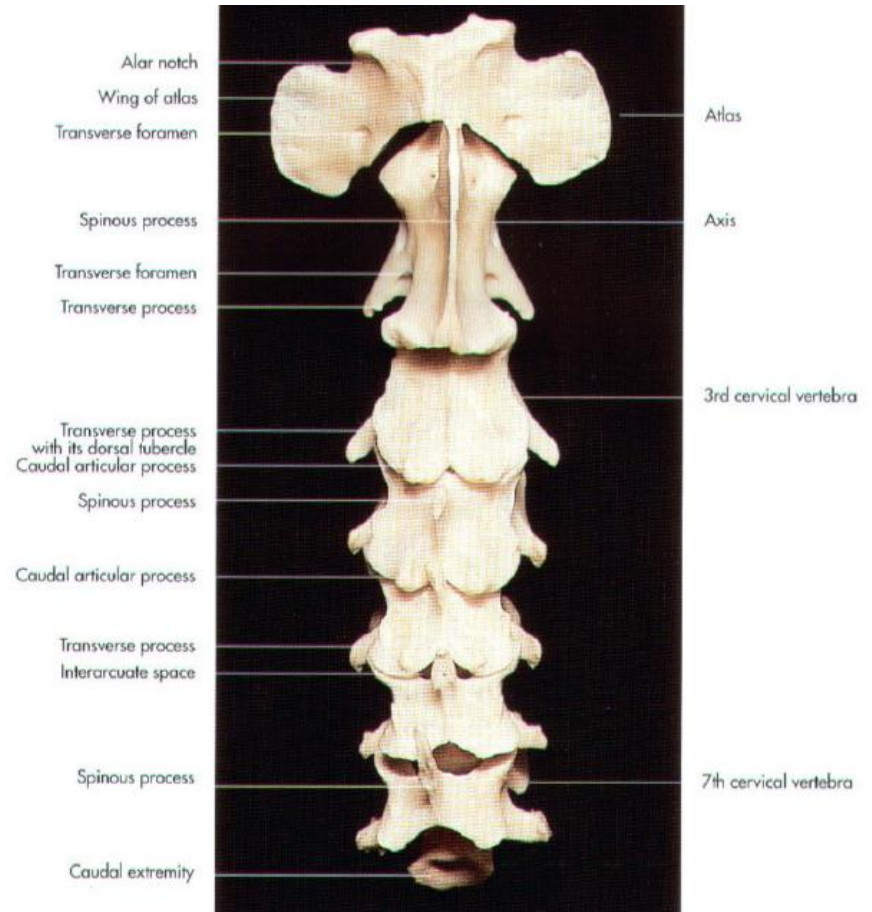
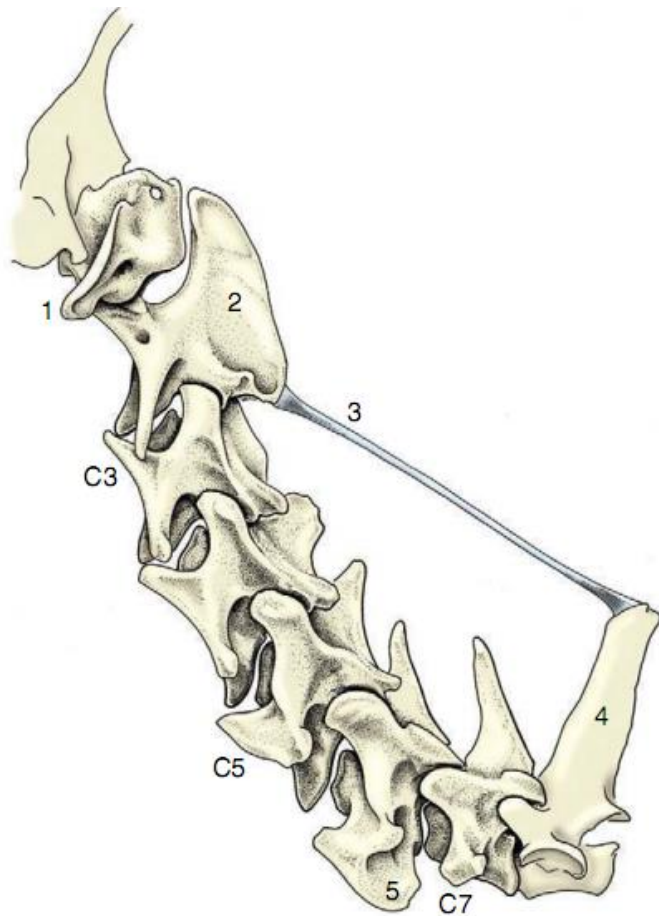
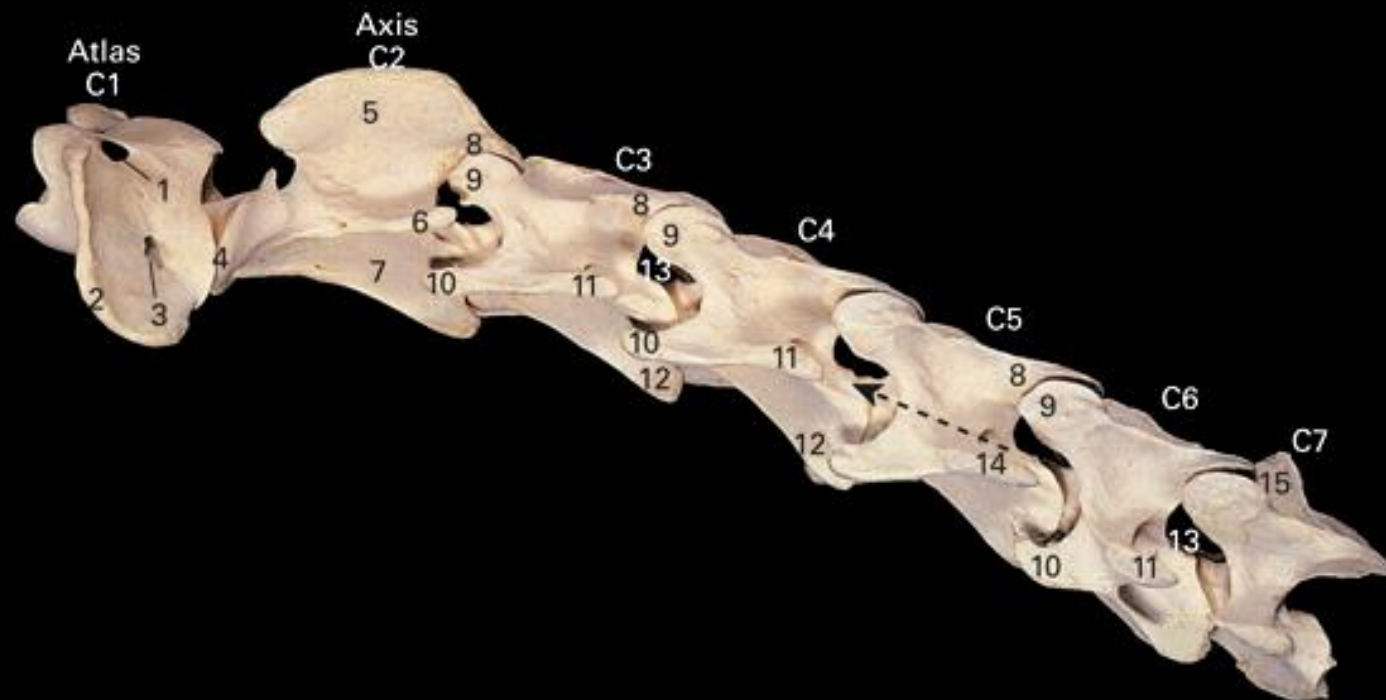


Figure 2-14 Bovine lumbar intervertebral disk. 1, Spinous process; 2, lamina; 3, synovial intervertebral joint; 4, articular process of adjacent vertebra; 5, vertebral canal with contents (spinal cord and meninges surrounded by epidural fat); 6, nucleus pulposus; 7, anulus fibrosus.

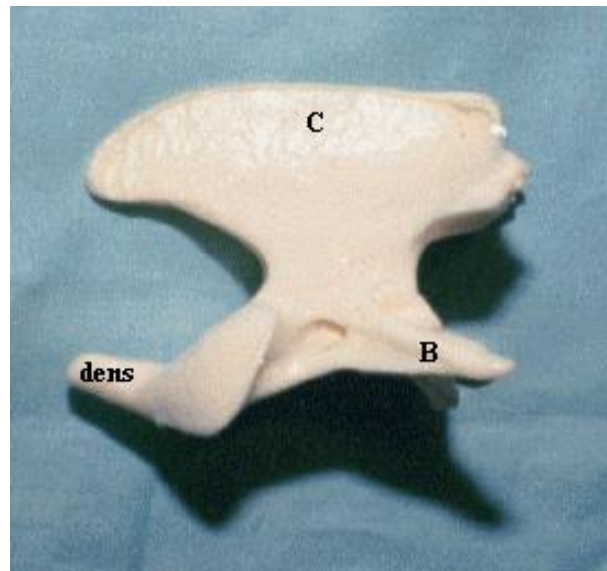
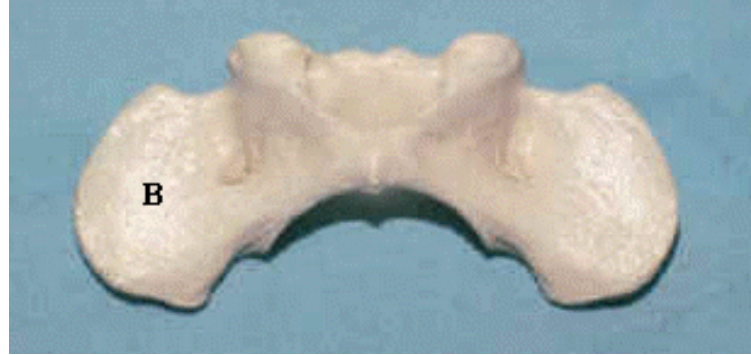مهره های گردنی (C)



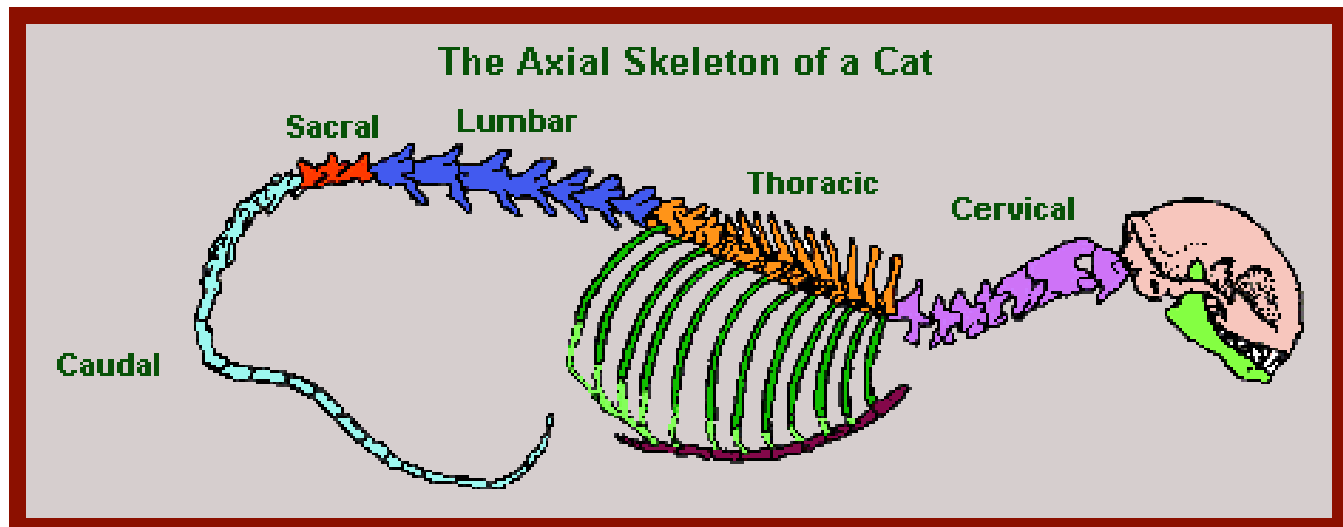


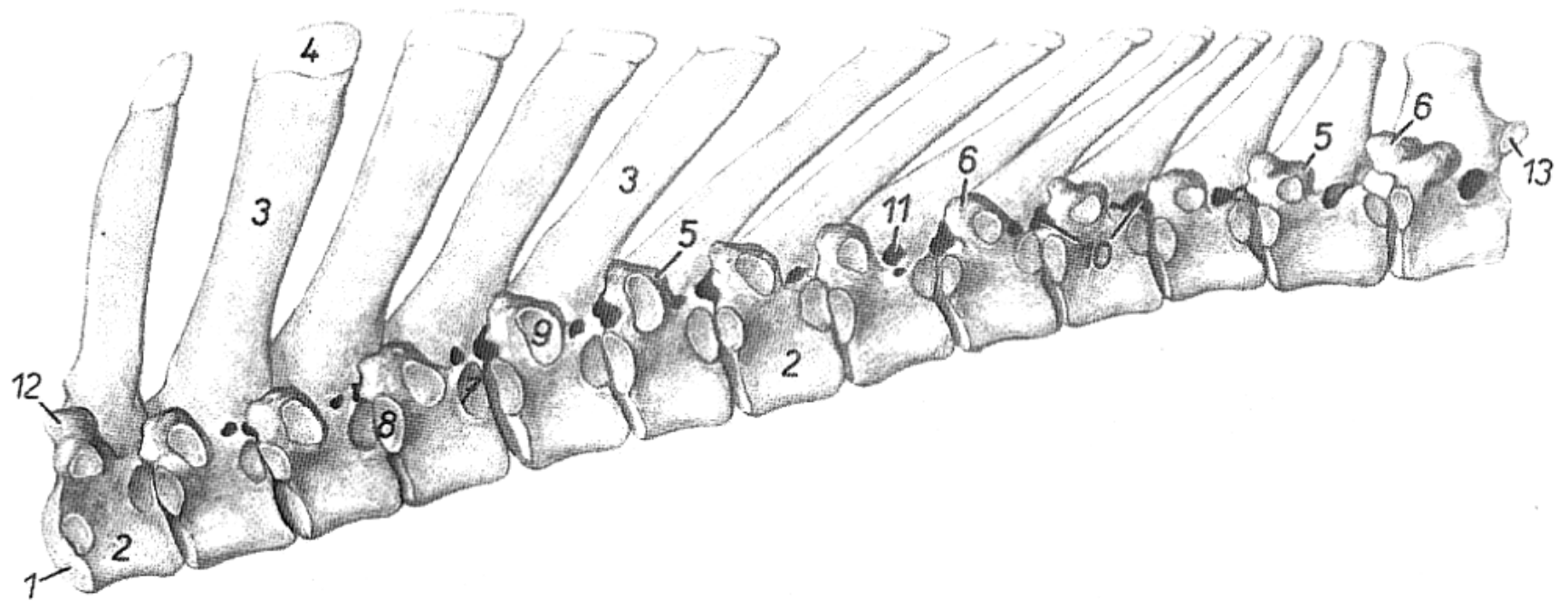
1. Alar foramen 2. Wing of atlas 3. Transverse foramen 4. Cranial articular process 5. Spine of axis
 6. Transverse process of axis 7. Body of axis 8. Caudal articular process 9. Cranial articular
 process 10. Cranial branch of transverse process 11. Caudal branch of transverse process
 12. Ventral Crest 13. Intervertebral foramen 14. Transverse foramen of C5 15. Spinous process of C7

مهره های اطلس و محوری متفاوت از مهره های دیگر هستند



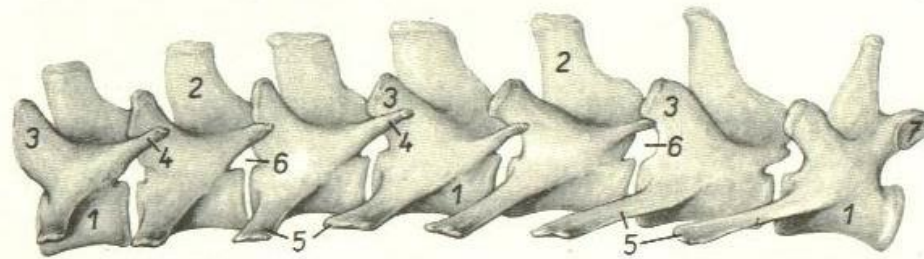
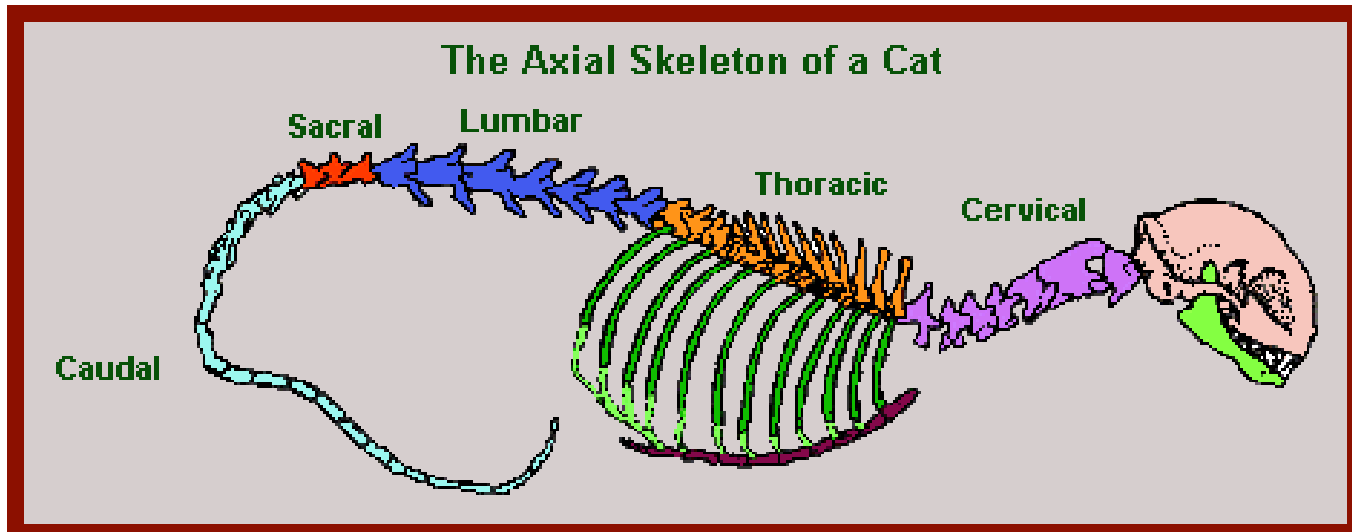
مهره های سینه ای (T)



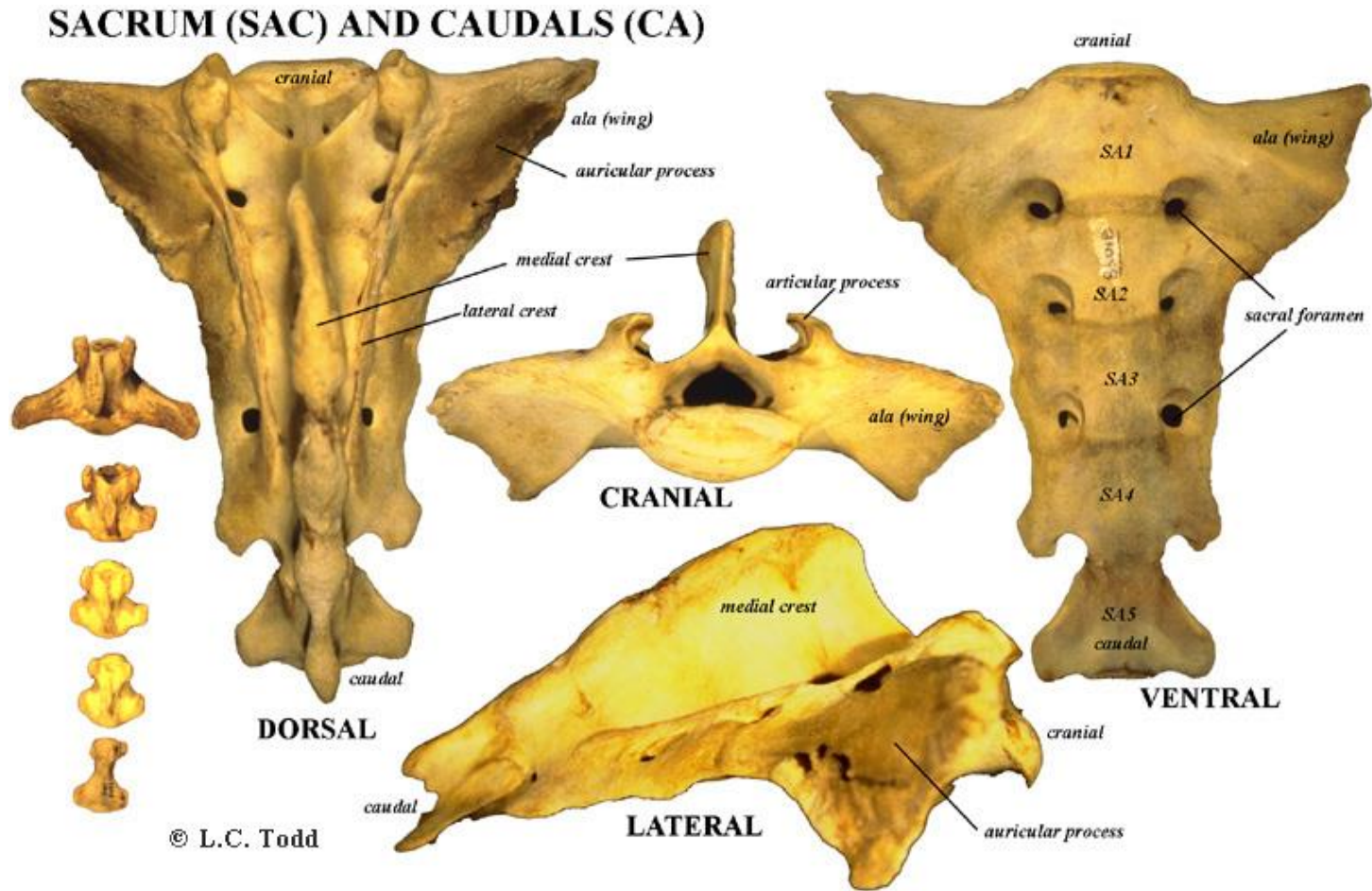


1)Cranial extremity of fist thoracic vertebra 2)Body of vertebra 3)Spinous P 4)Tuberosity of spinous P 5)Transverse P 6)Mamillary P 7)Coudal costal facet 8)Cranial costal facet 9)Transverse costal fovea 10)Intervertebral foramina 11)Lteral vertebral foramenina 12)Crania articular P. of first vertebra 13)Coudal articular P.Of 13th thoracic vertebra

مهره های کمری (L)

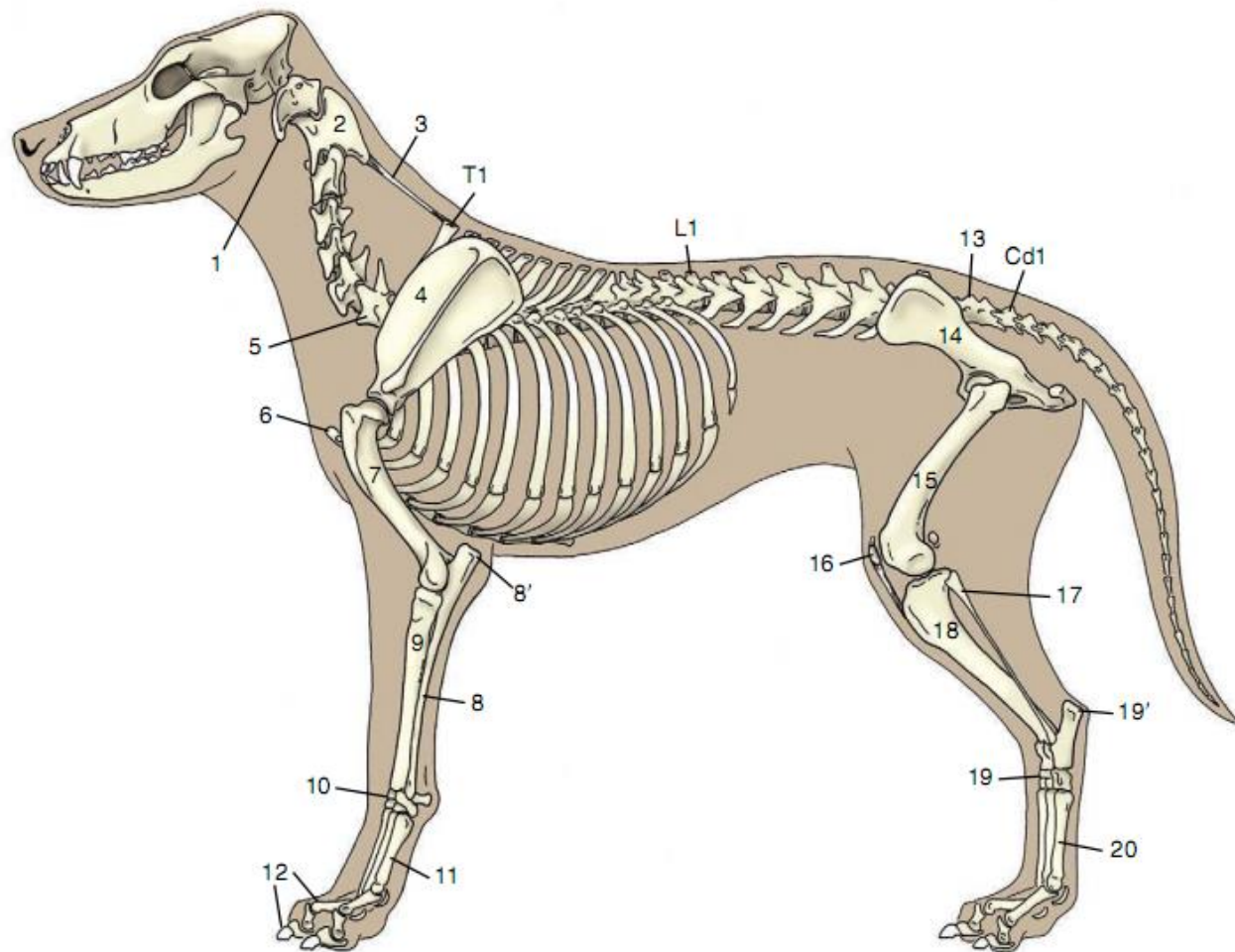


مهره های خاجی و دمی (S & Cd)

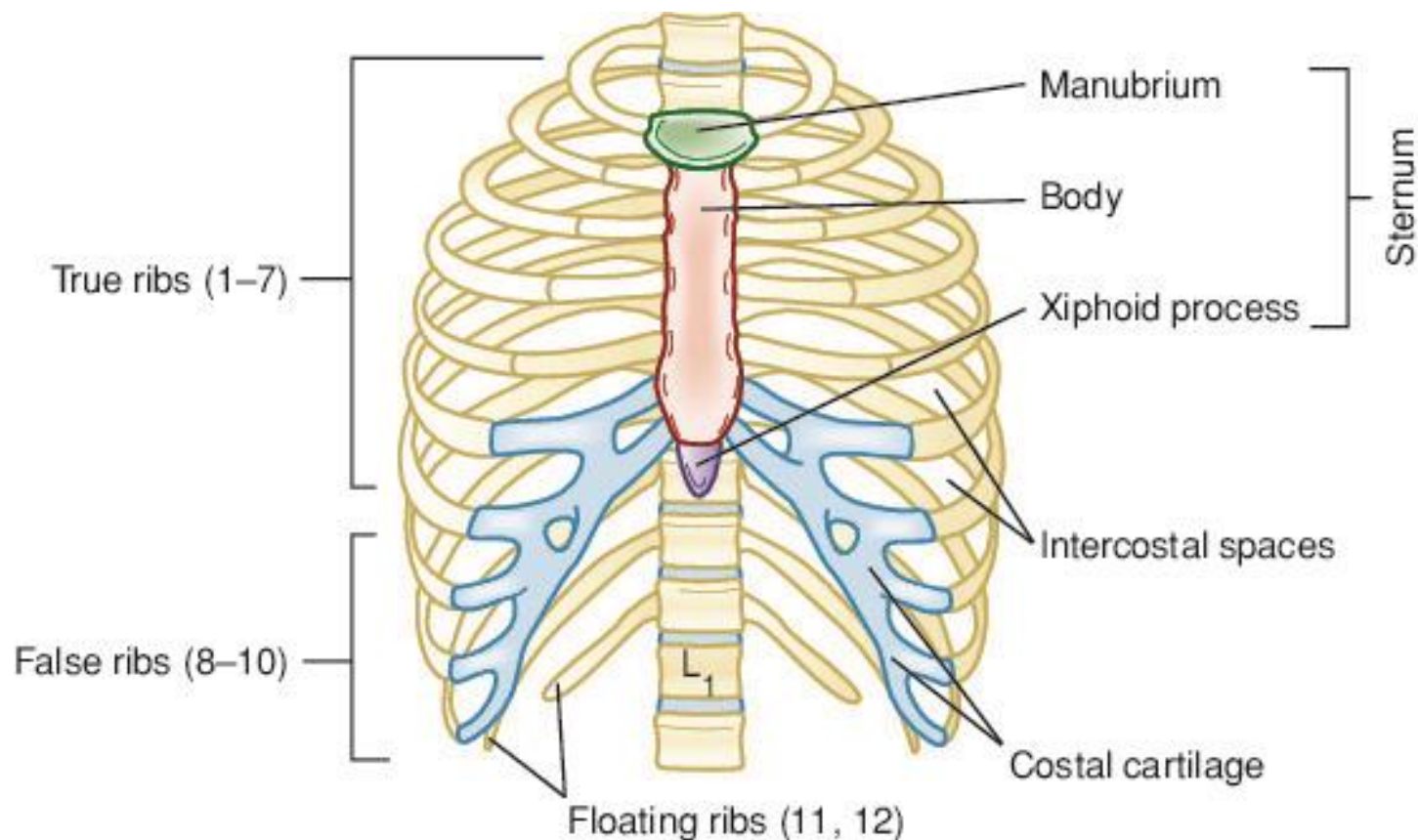


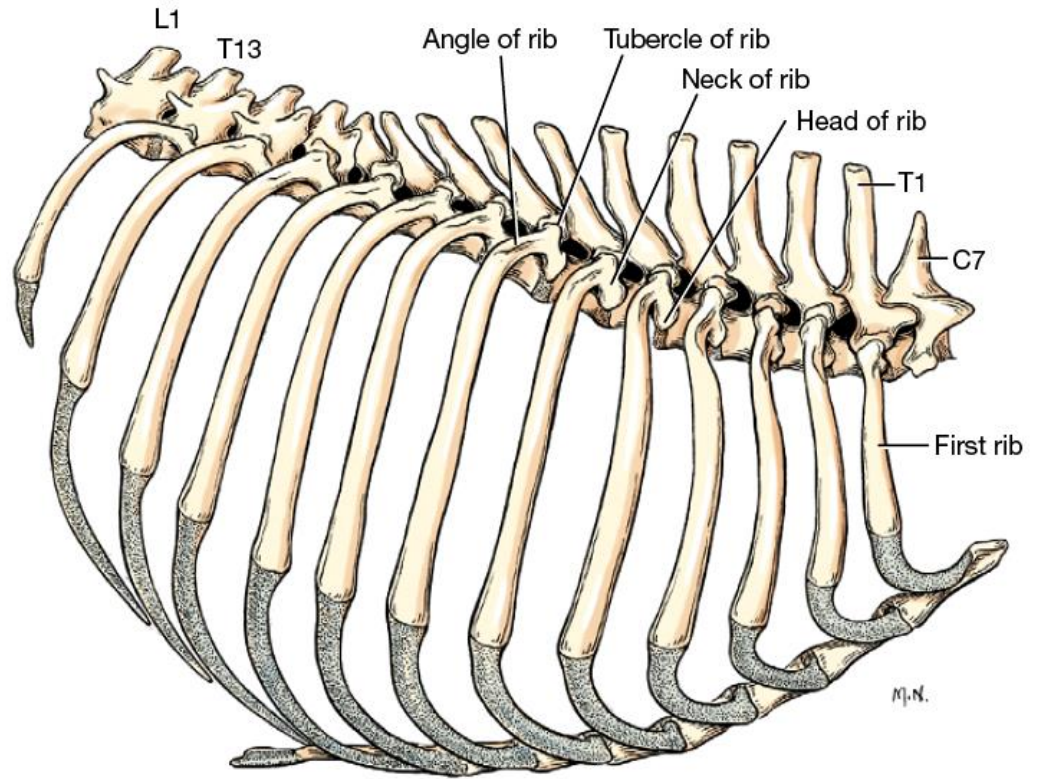
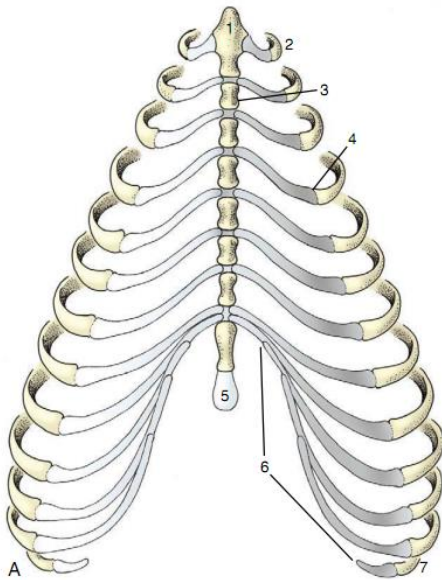
دنده ها

Ribs



نمای جلویی قفسه سینه انسان





نمای شکمی قفسه سینه سگ

نمای جانبی قفسه سینه سگ

ساختار های موجود در یک دنده

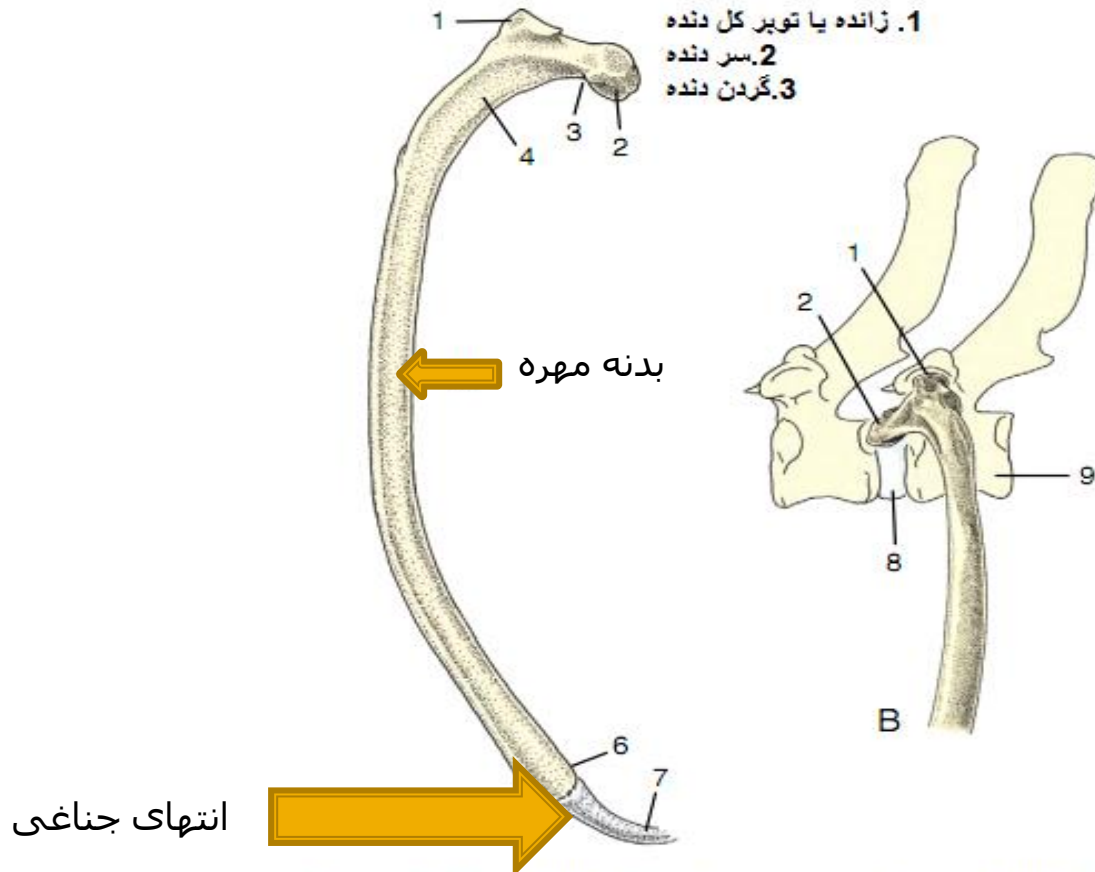
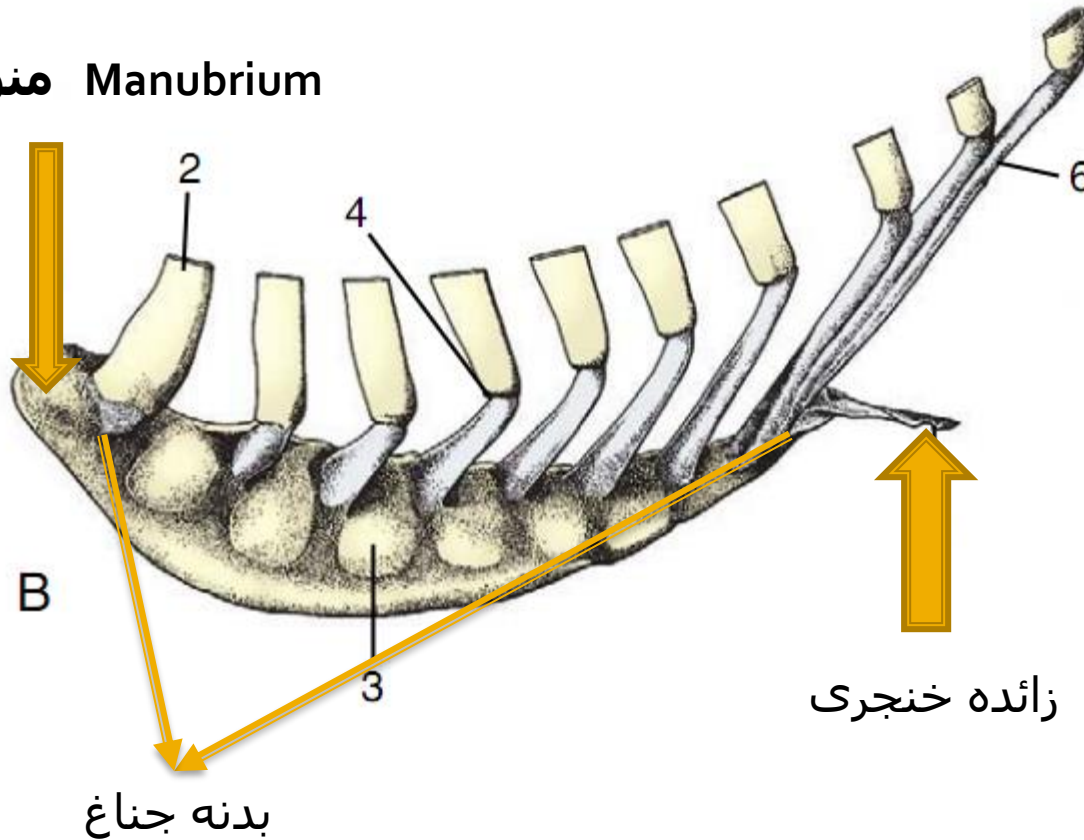


Figure 2-16 A, Left rib of a dog, caudal view. B, Left rib of a dog articulating with two vertebrae, lateral view. 1, Tubercle; 2, head; 3, neck; 4, angle; 5, body; 6, costochondral junction; 7, costal cartilage; 8, intervertebral disk; 9, vertebra of same number as rib.

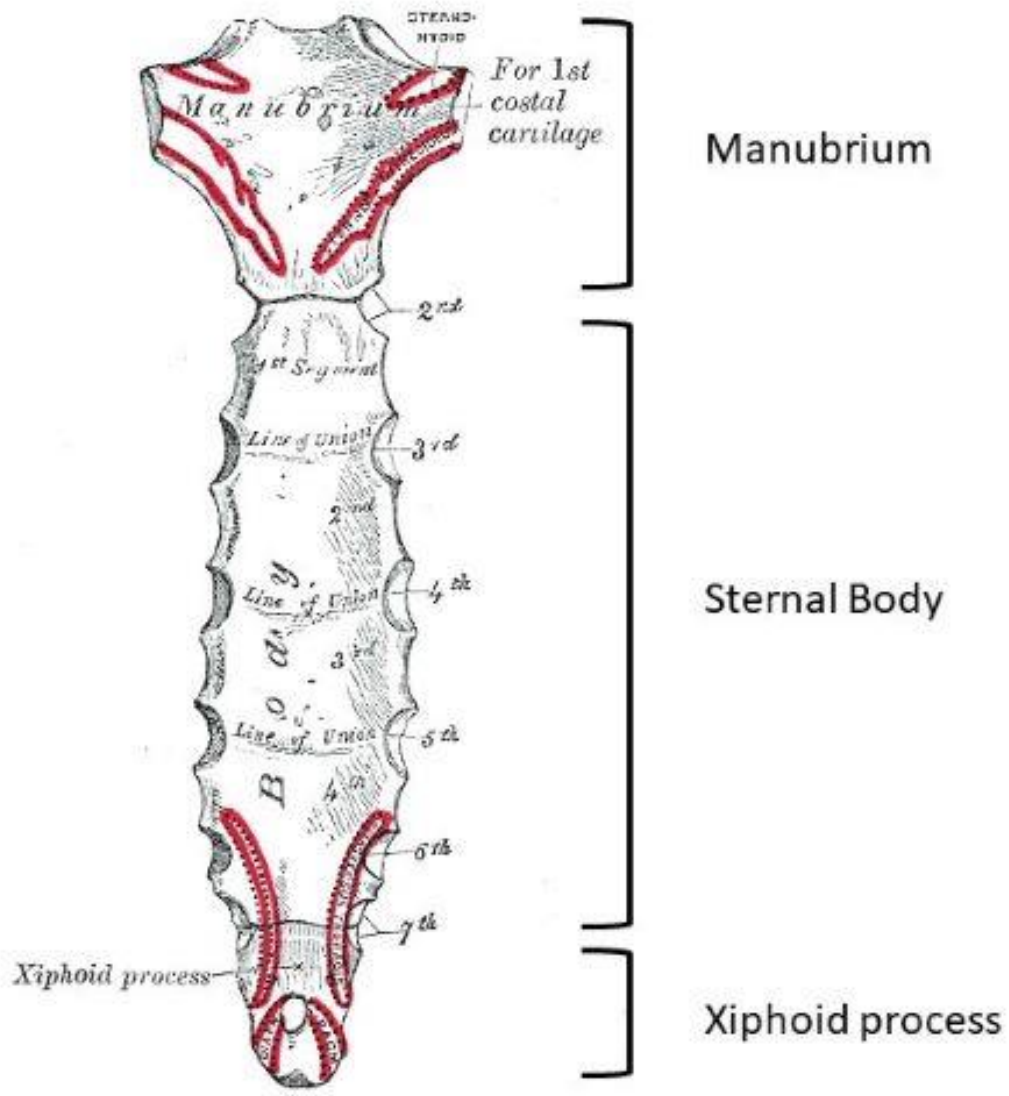
جناغ

Sternum

منوبريوم Manubrium



Sternum



استخوان های اندام حرکتی قدامی

fore limb Bones

1-Shoulder girdle;(scapula) ■

■ استخوان کتف

2-Brachium(arm);Humerus ■

■ استخوان بازو

3-Antebrachium(forearm) :Radius&Ulna ■

■ استخوان زند زبرین و زیرین

4-Manus ;Carpus&Metacarpus&Digits

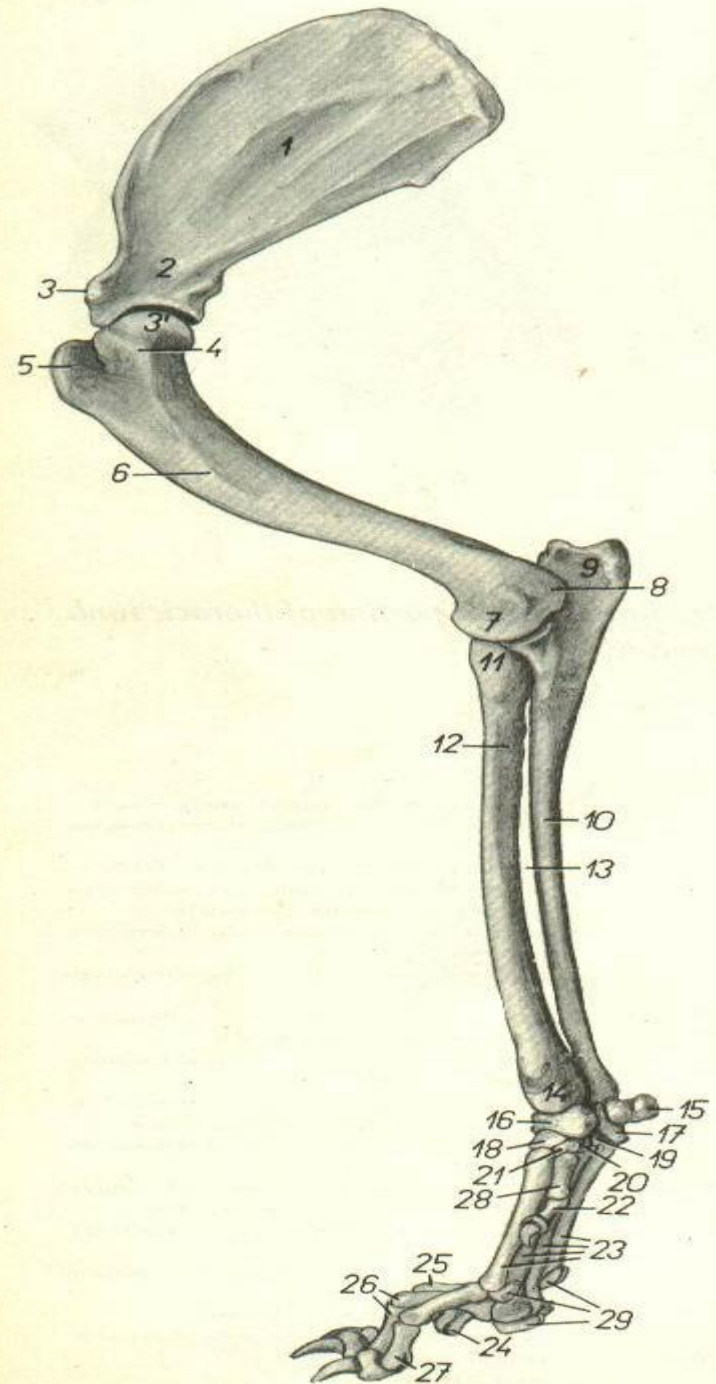
مچ دست ، قلم دست ، انگشتان

کمر بند سینه ای
Thoracic girdle

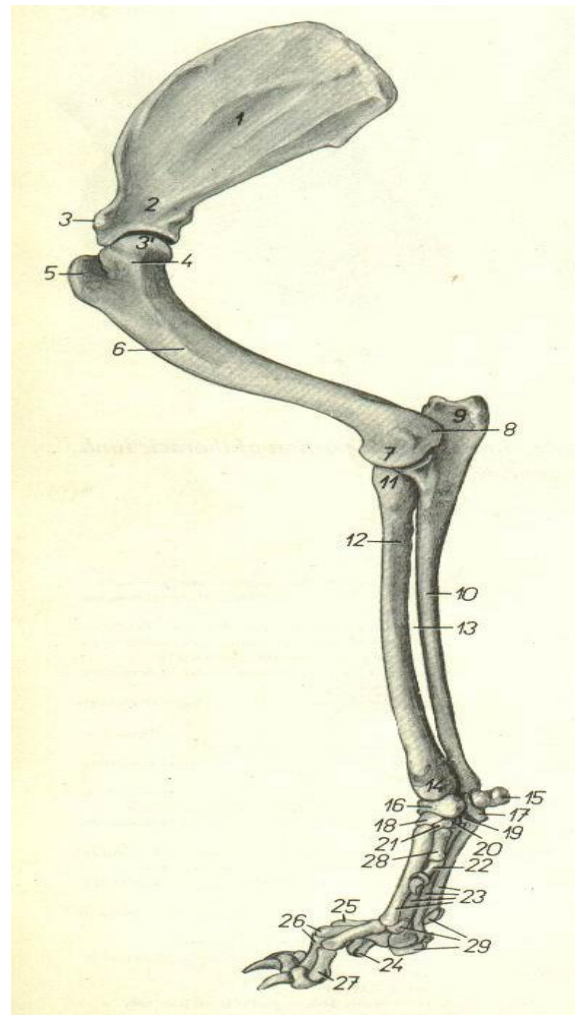
بازو
Brachium

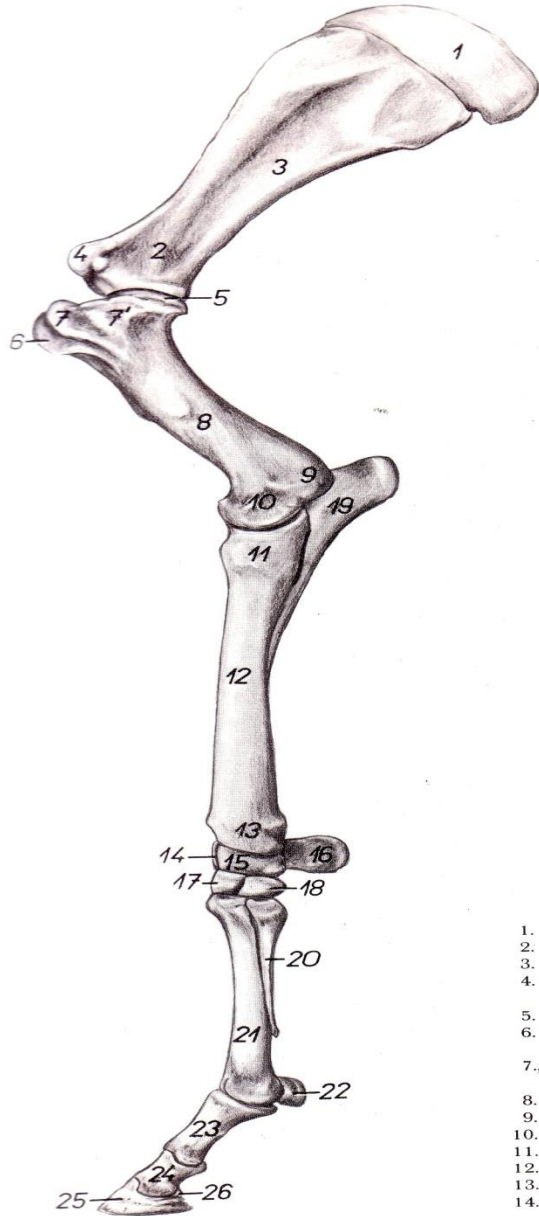
ساعد
Antebrachium

پنجه دست
Manus

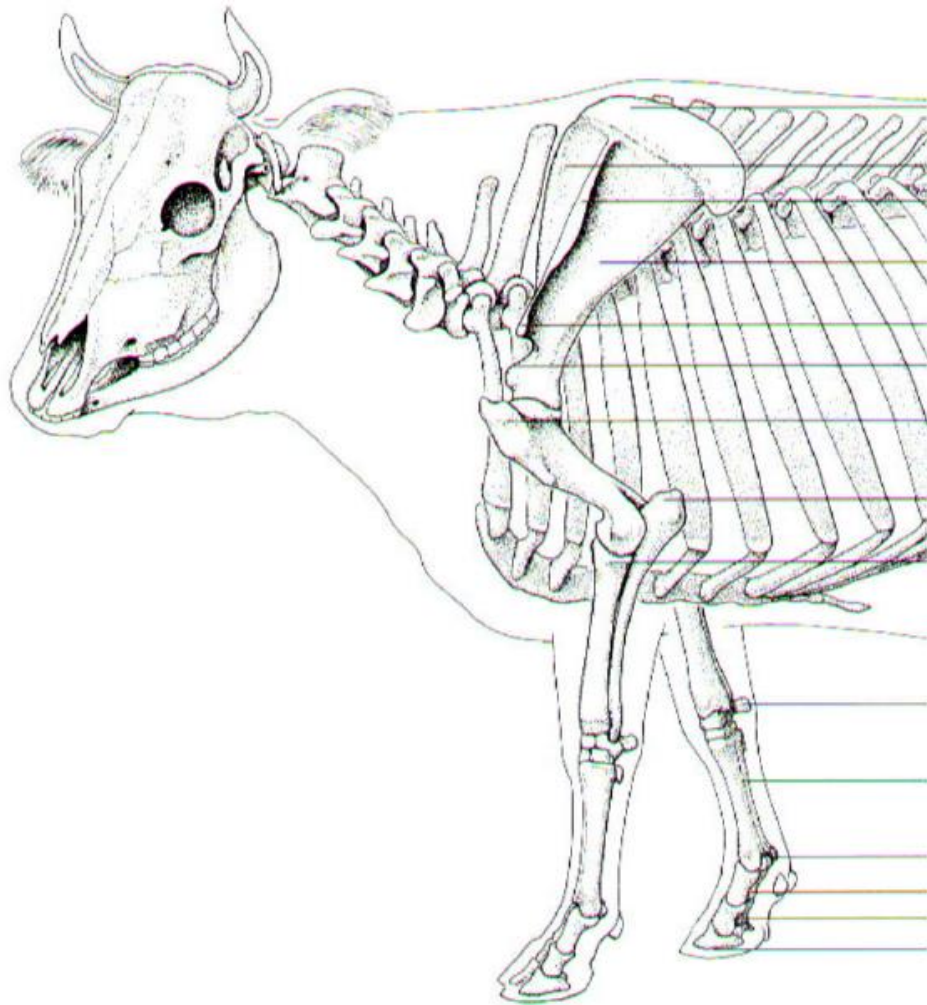


fore limb اندام حرکتی قدامی





- 1. *car*
- 2. *colt*
- 3. *fos*
- 4. *tub*
bei
- 5. *caj*
- 6. *tul*
be
- 7., 7'.
hu
- 8. *coi*
- 9. *epi*
- 10. *con*
- 11. *caj*
- 12. *coi*
- 13. *tro*
- 14. *os*
ca



Scapular cartilage

Supraspinous fossa

Spine of scapula with
tuberosity of scapular spine

Infraspinous fossa

Acromion

Supraglenoid tubercle

Greater tubercle of humerus

Olecranal tuberosity

Head of radius

Accessory carpal bone

3rd and 4th metacarpal bone

Proximal sesamoid bones

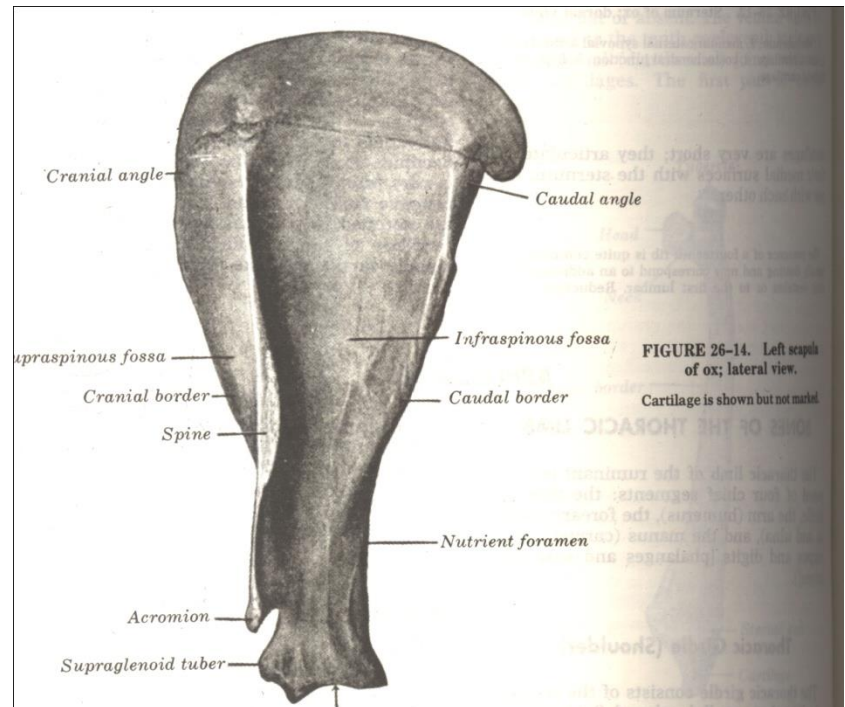
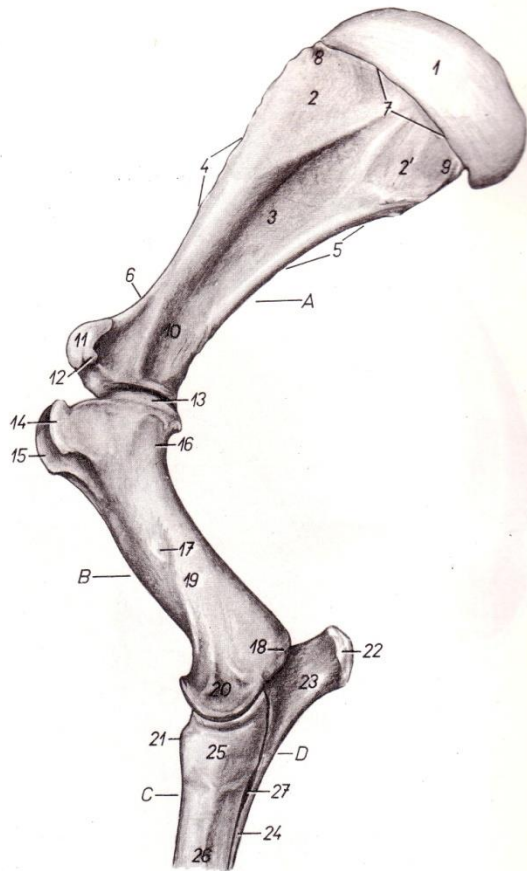
Proximal phalanx

Middle phalanx

Distal phalanx

كتف

Scapula



Cranial angle

Caudal angle

Suprascapular fossa

Infrascapular fossa

Cranial border

Caudal border

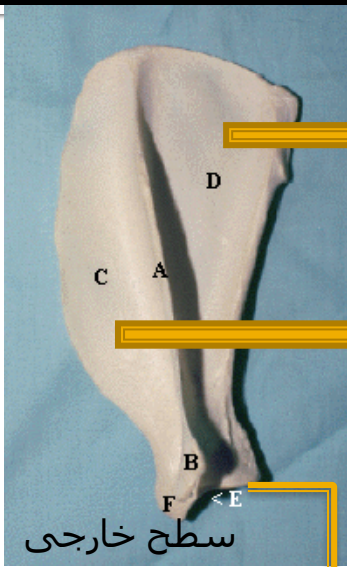
Spine

Nutrient foramen

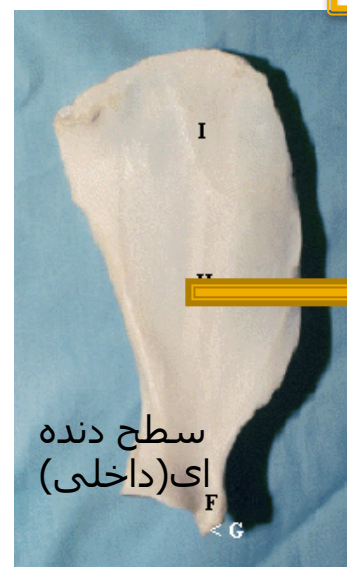Acromion

Supraglenoid tuber

FIGURE 26-14. Left scapula of ox; lateral view. Cartilage is shown but not marked.

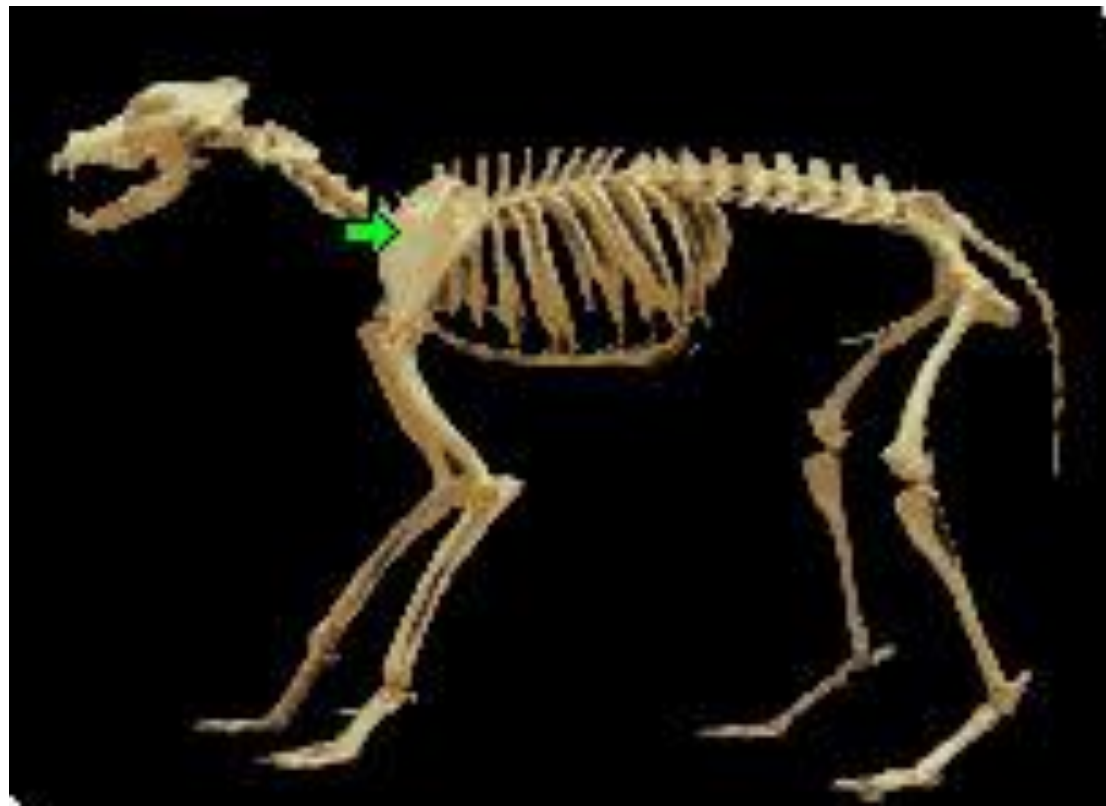

گودی زیر شوکی



گودی زیر کتفی

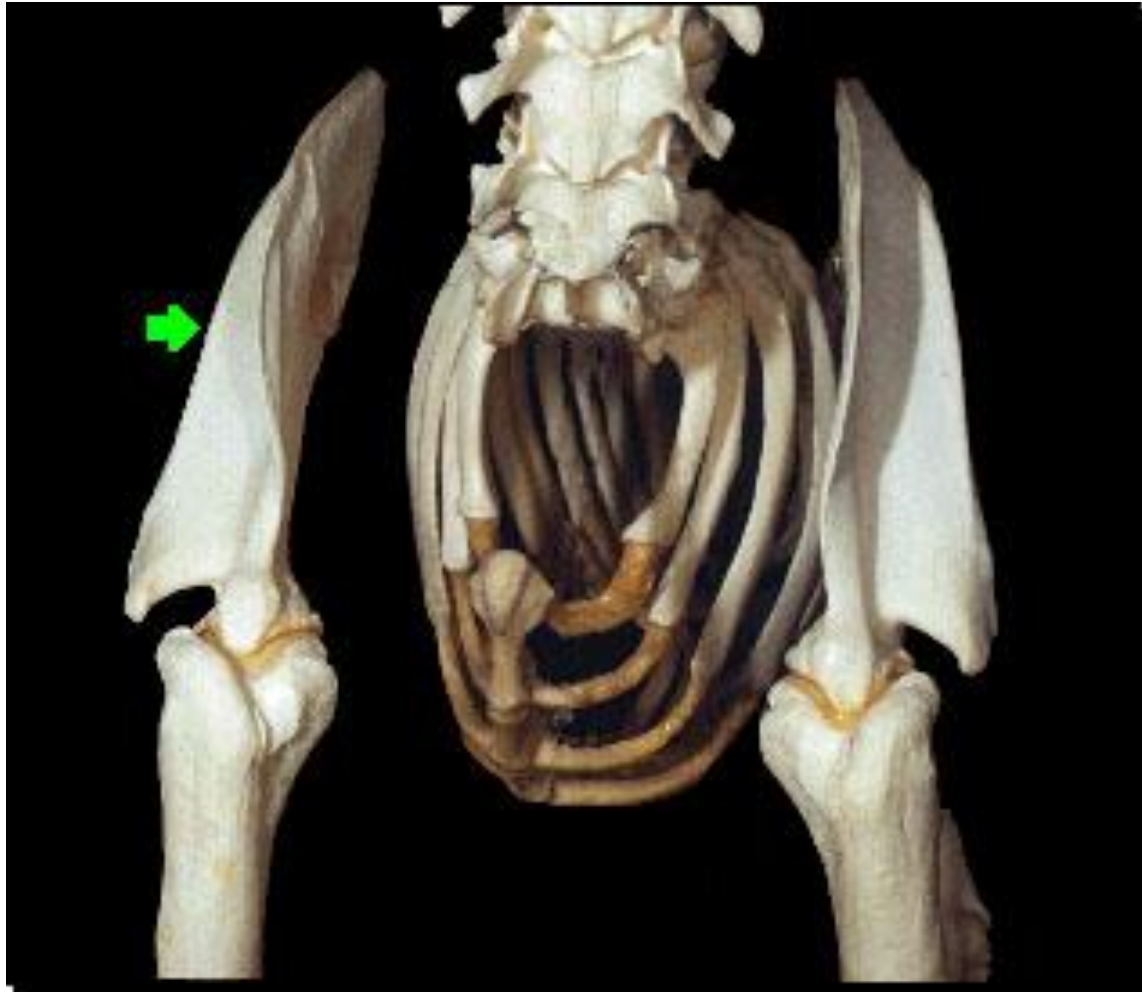گودی فوق شوکی



گلوئید

سطح دنده ای (داخلی)

سطح خارجی



بازو

Humerus

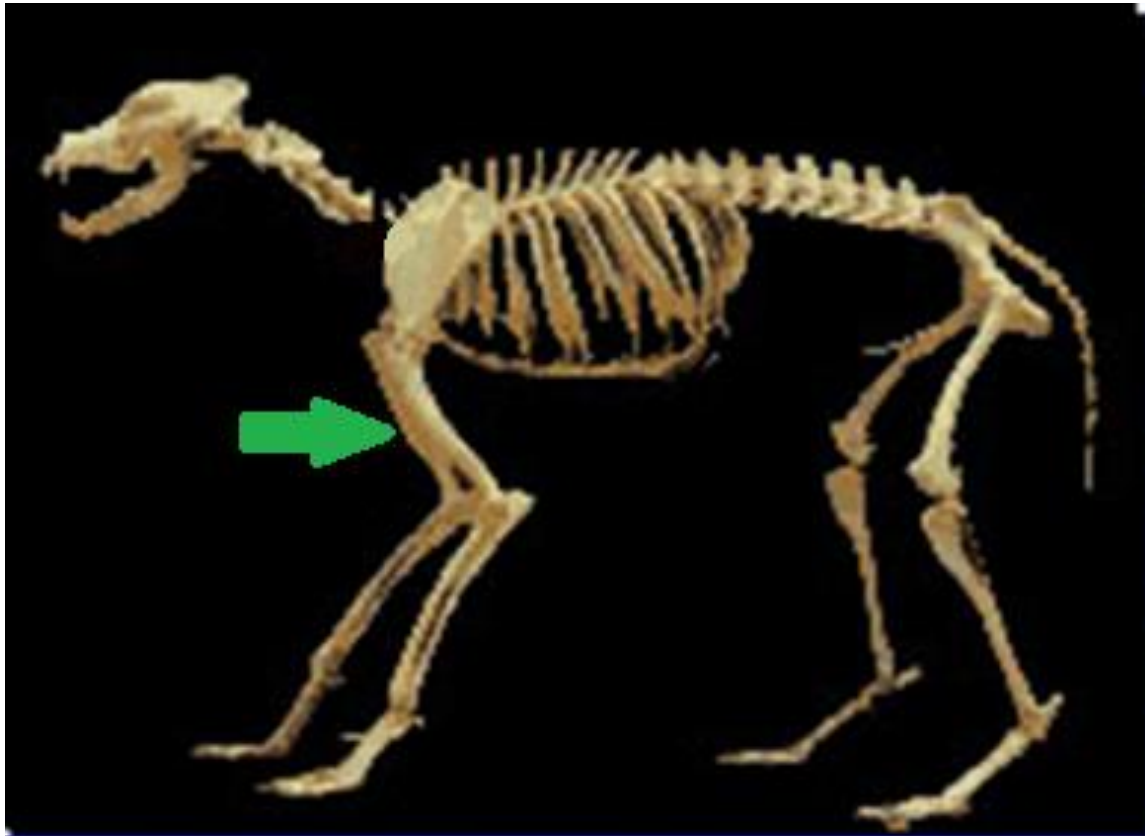


FIGURE 26-15. Left humerus of ox; lateral view.

1, Head; 2, neck, 3, 3', major (lateral) tuberosity; 4, rough prominence for attachment of infraspinatus tendon; 5, deltoid tuberosity; 6, radial fossa; 7, capitulum; 8, lateral epicondyle; 9, medial epicondyle; 10, olecranon fossa.

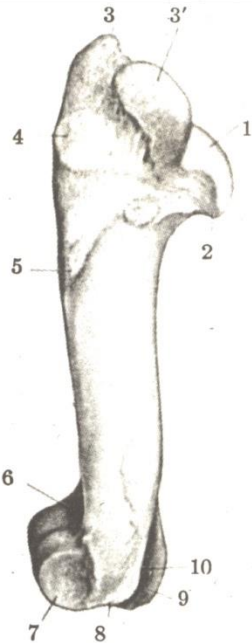


FIGURE 26-15.

FIGURE 26-16. Left humerus of ox; cranial view.

1, Major (lateral) tuberosity; 2, minor (medial) tuberosity; 3, intertuberal groove; 4, rough prominence for attachment of infraspinatus tendon; 5, deltoid tuberosity; 6, teres major tubercle; 7, (musculospiral) groove for brachialis; 8, radial fossa; 9, trochlea; 10, capitulum.

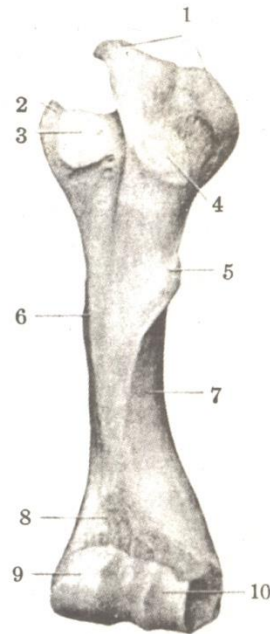
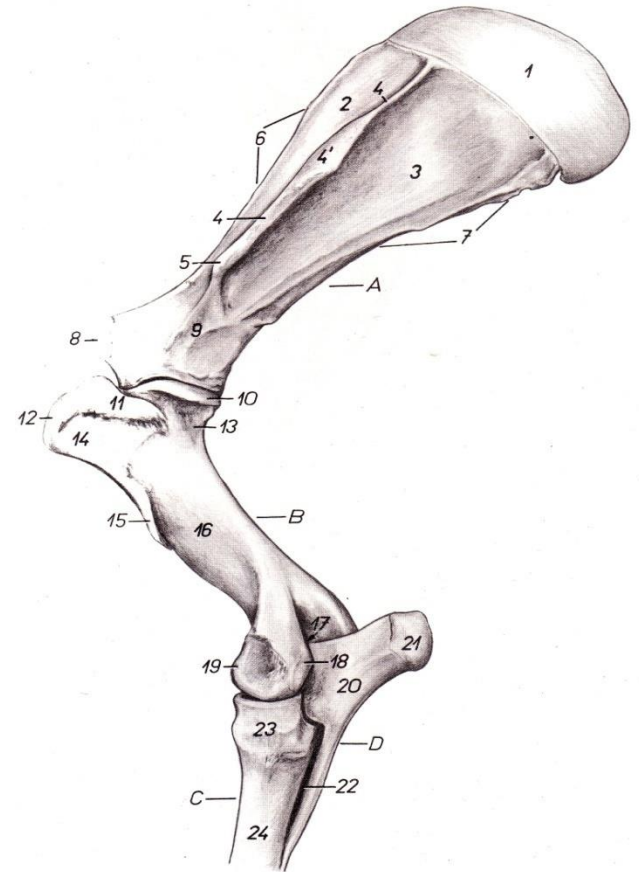
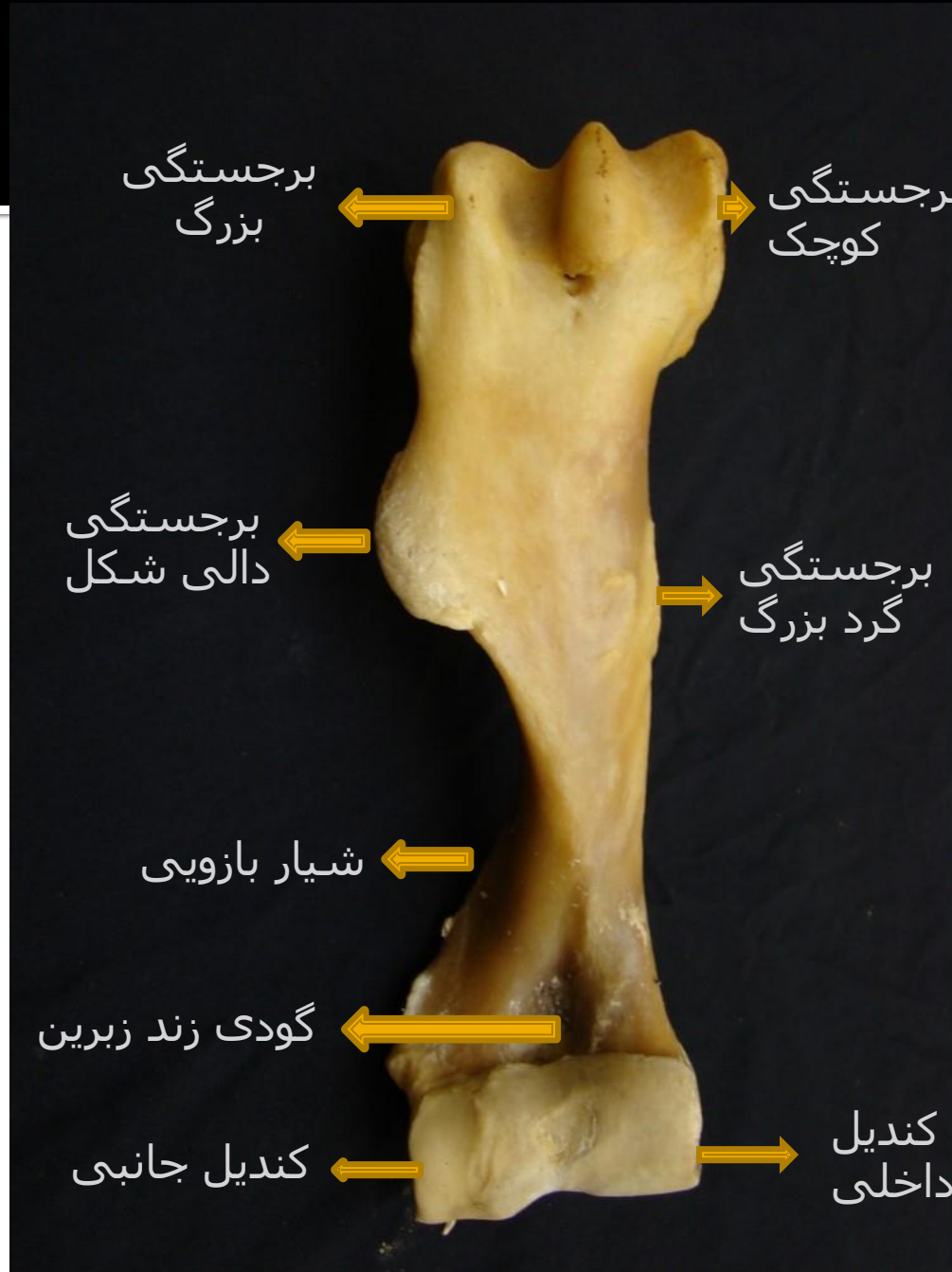


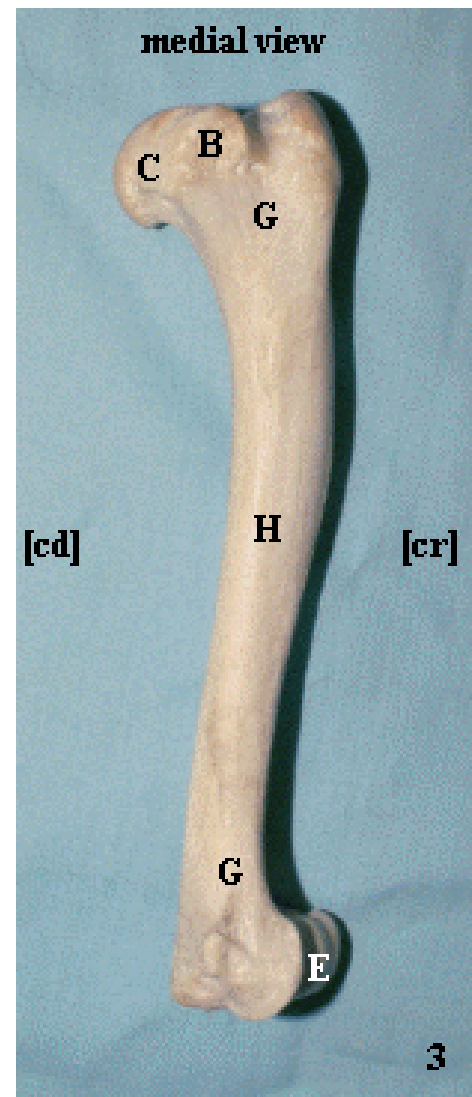
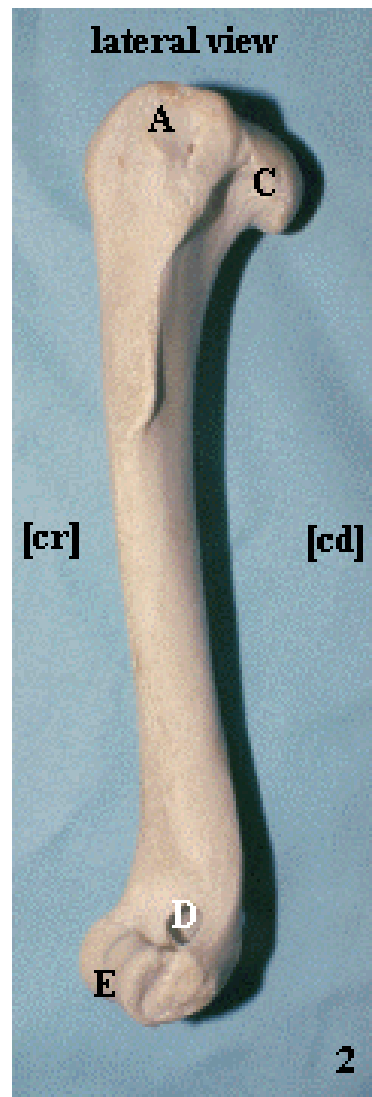
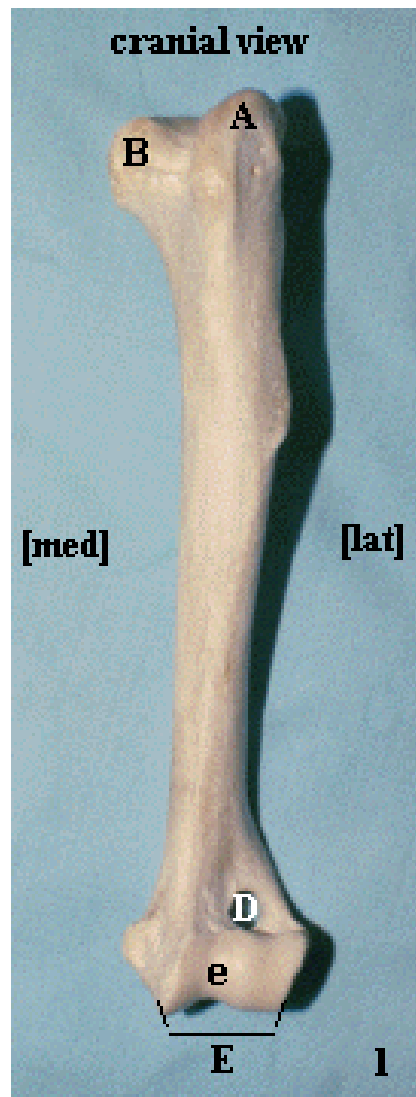
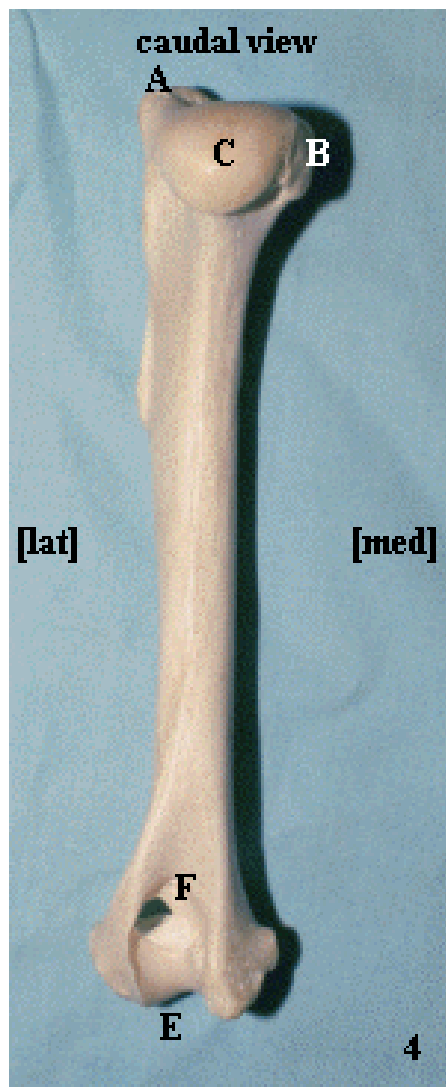
FIGURE 26-16.



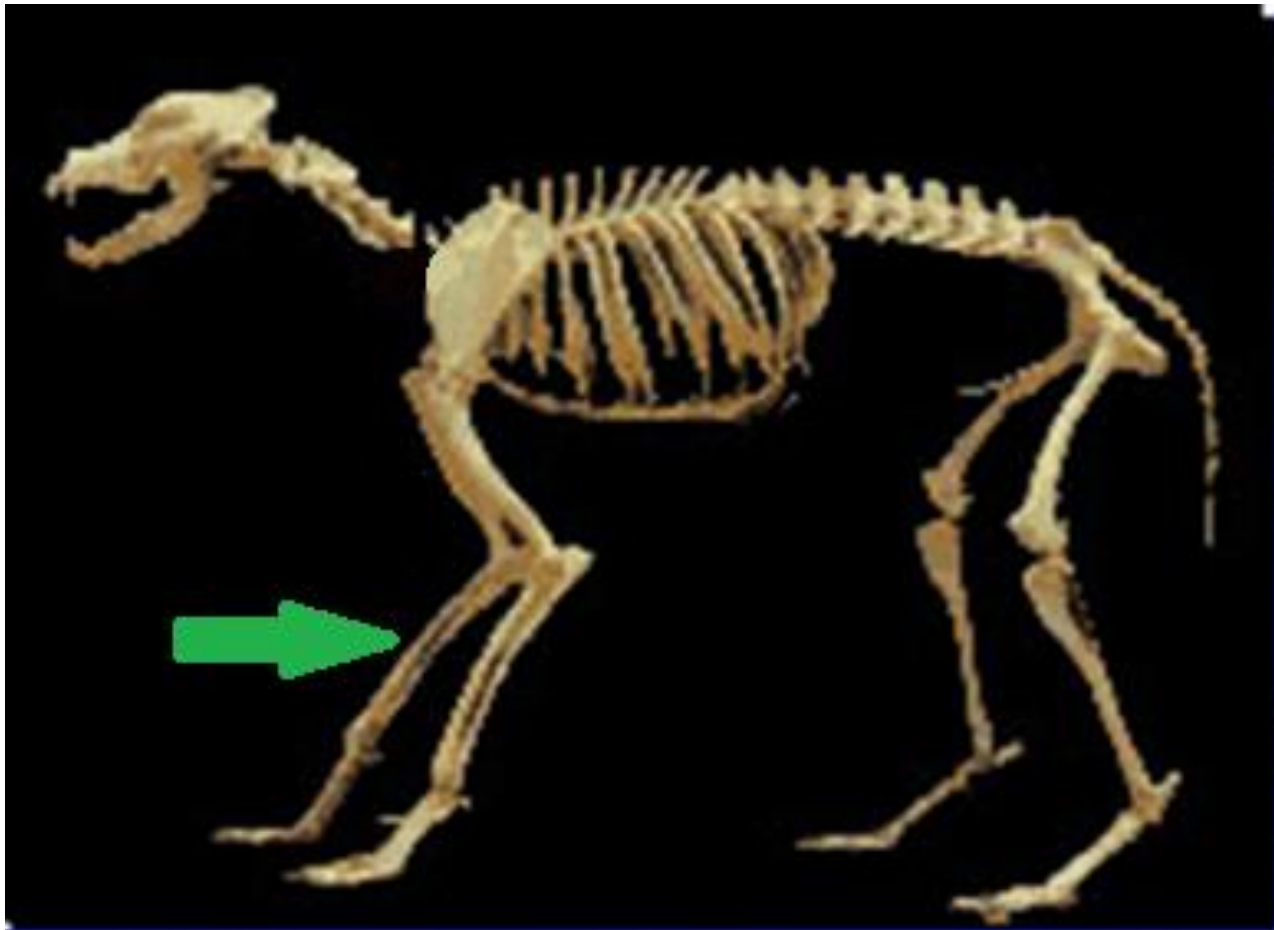
Horse



بازو در اسب نمای
جلویی



Radius & Ulna



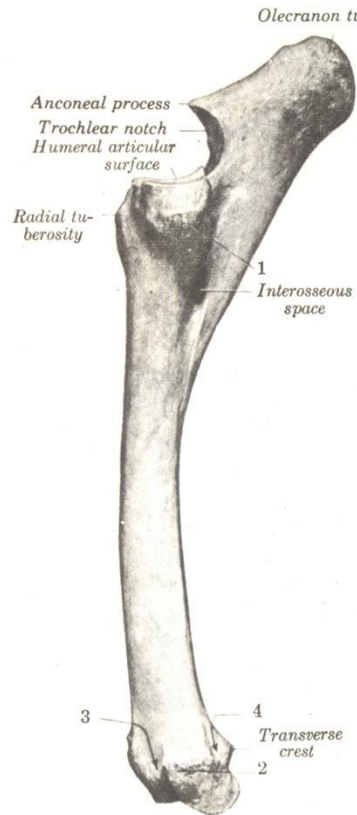


FIGURE 15-41. Left radius and ulna of horse; lateral view.

- 1, Tuberosity for attachment of lateral collateral ligament of elbow joint, and extensor digitorum communis and lateralis;
- 2, tuberosity for attachment of lateral collateral ligament of carpal joint;
- 3, groove for common digital extensor tendon;
- 4, groove for lateral digital extensor tendon.

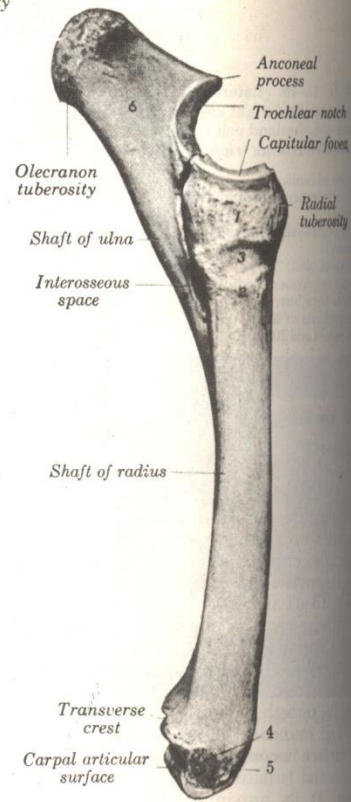
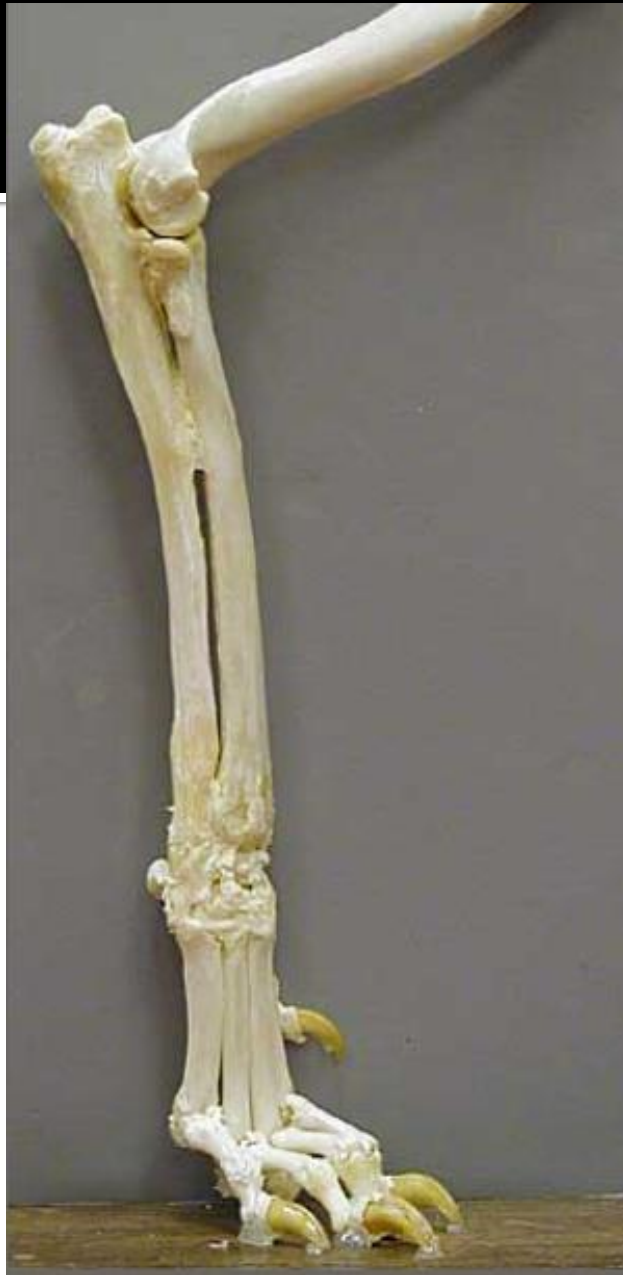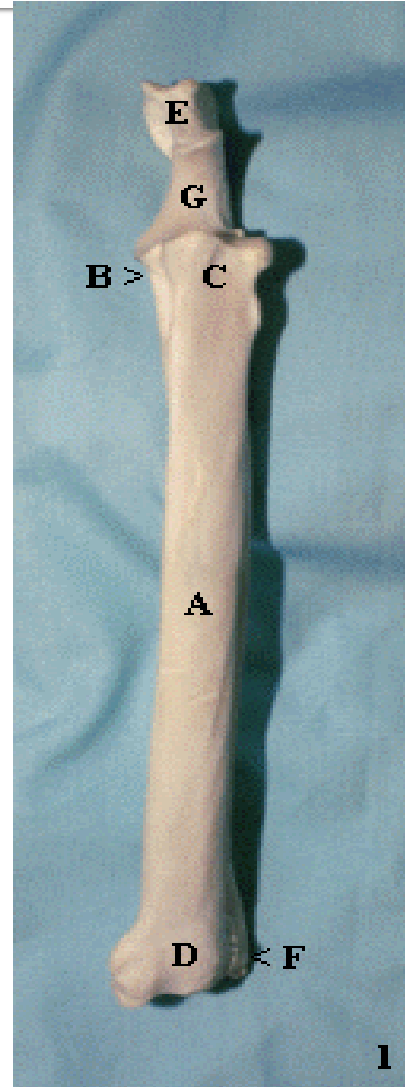
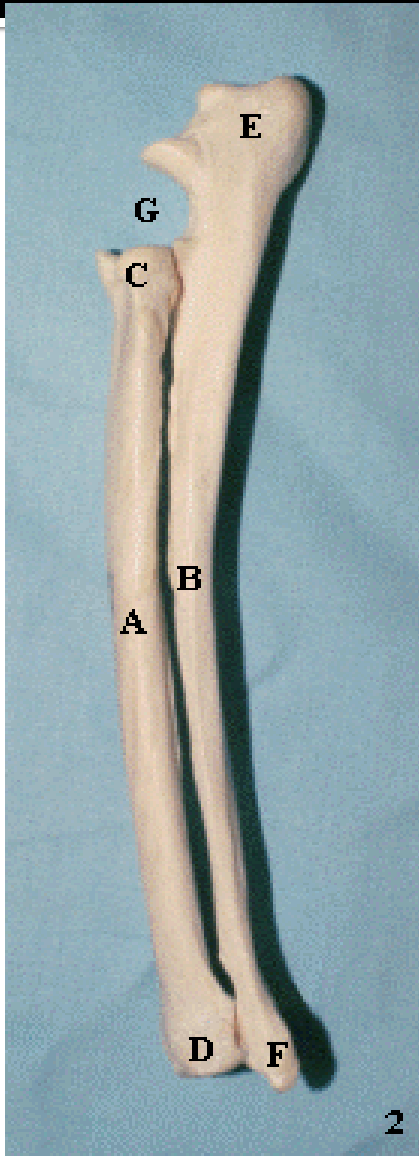
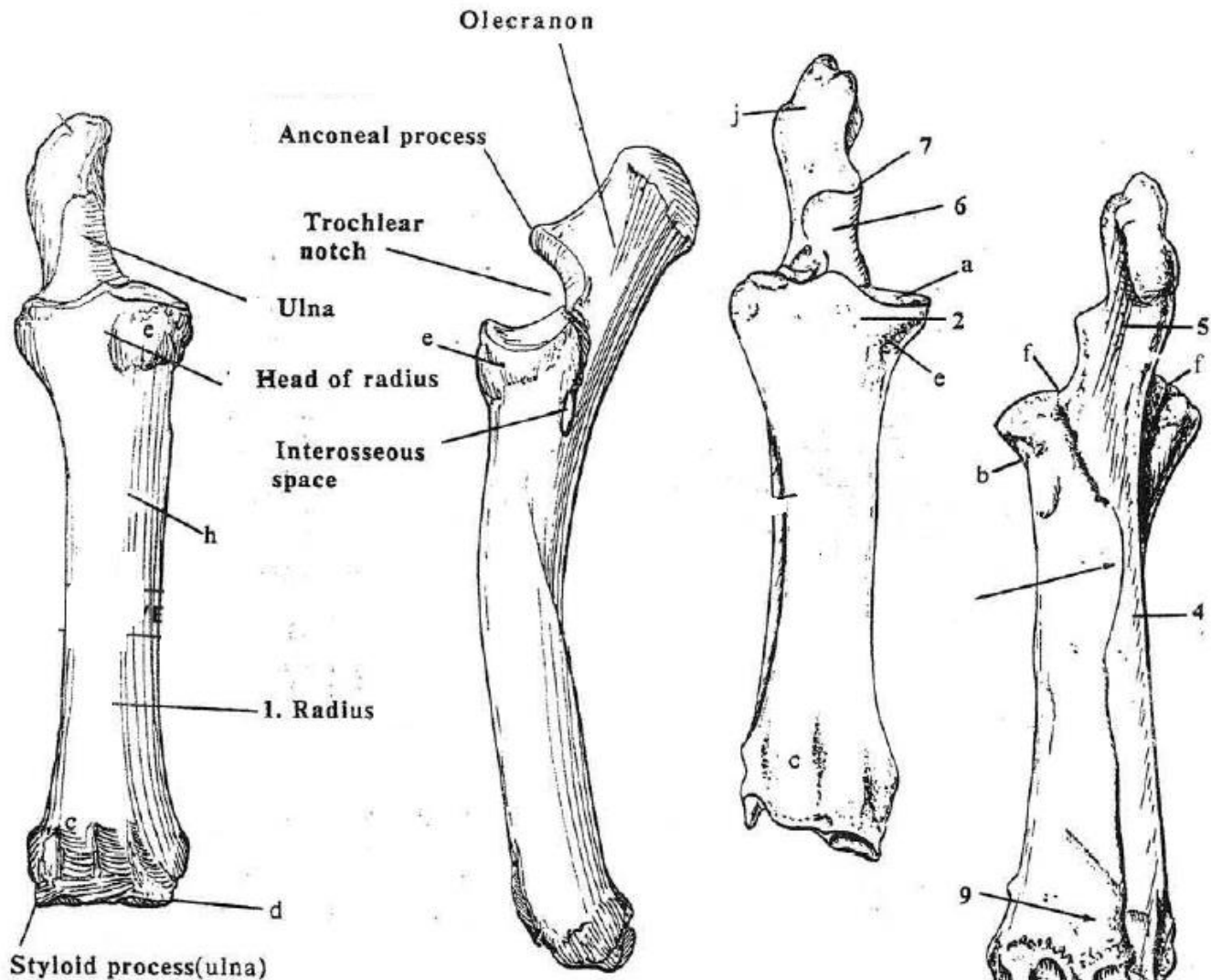


FIGURE 15-42. Left radius and ulna of horse; medial view.

- 1, Tuberosity for attachment of short part of medial collateral ligament of elbow;
- 2, prominence for long part of same;
- 3, groove for end of brachialis muscle;
- 4, tuberosity for attachment of medial collateral ligament of carpal joint;
- 5, oblique groove for tendon of abductor digiti I longus;
- 6, olecranon.



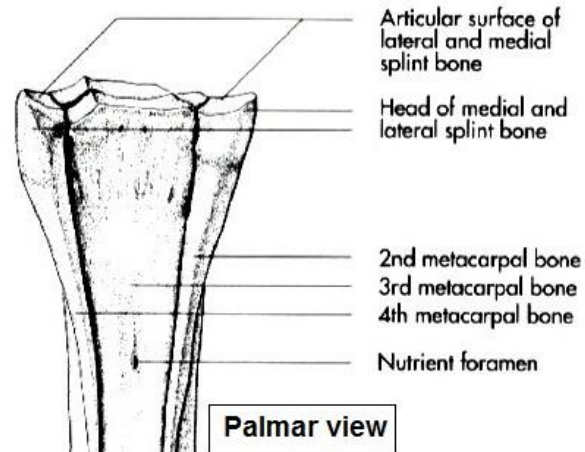
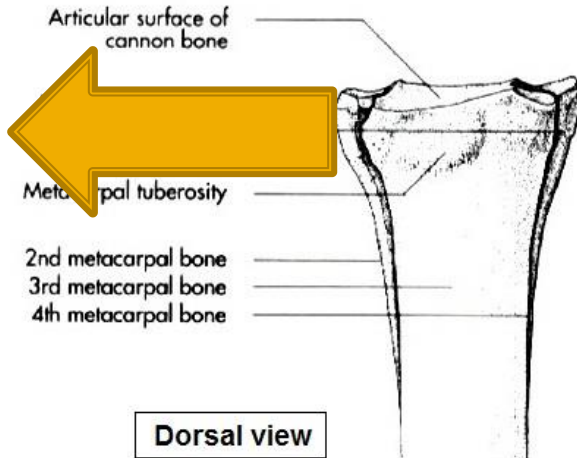




Metacarp

قلم دست

قاعده




Buttons of medial and lateral splint bone

Nutrient foramen

Eminence and Depression for ligament attachment

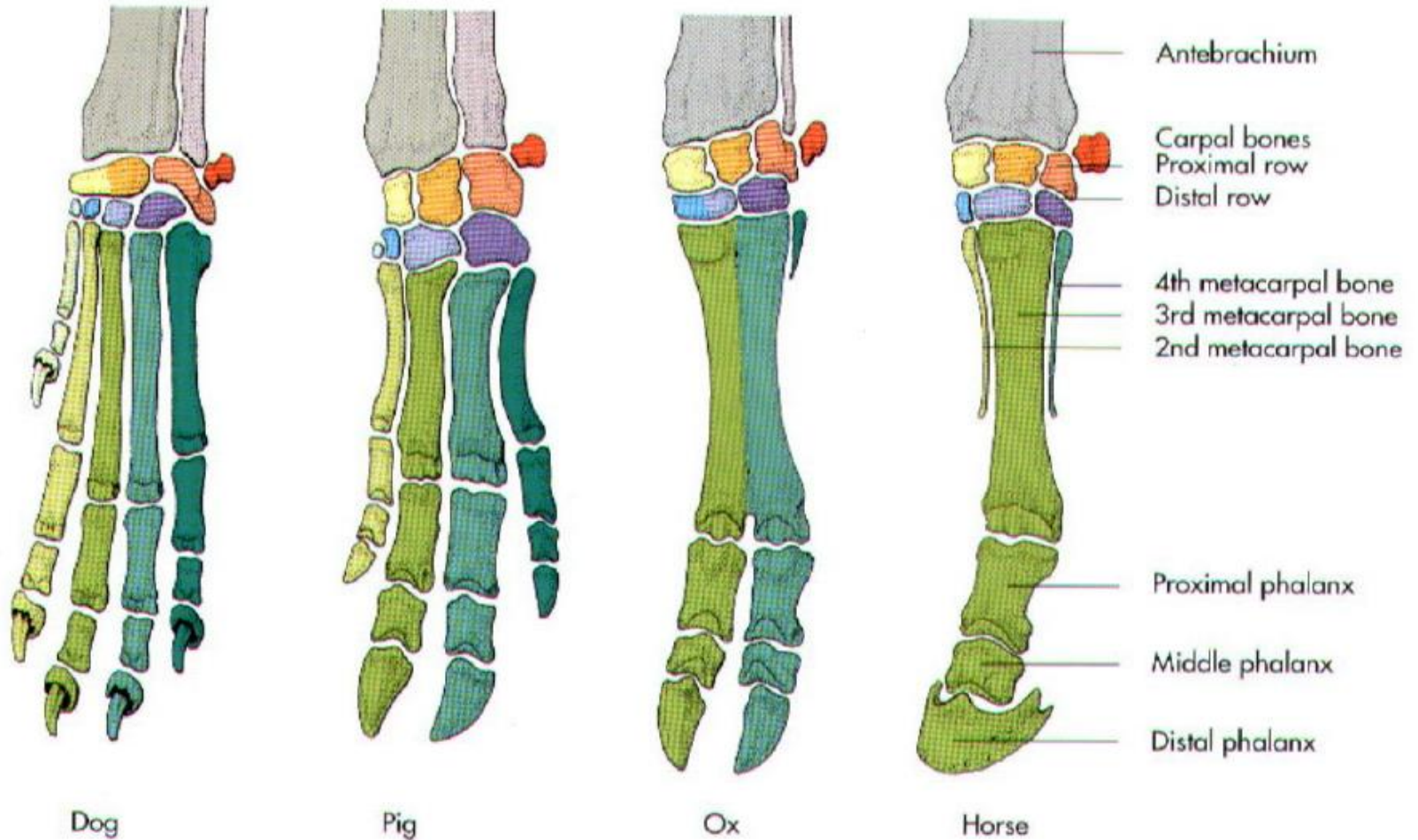
Metacarpal trochlea with sagittal crest

سر (قرقره)



Carpal & Metacarpal bones

استخوان های مچ دست و قلم دست



Digits

انگشتان

کنجدي بالايي

بند بالايي

بند مياني

کنجدي پائيني

بند پائيني

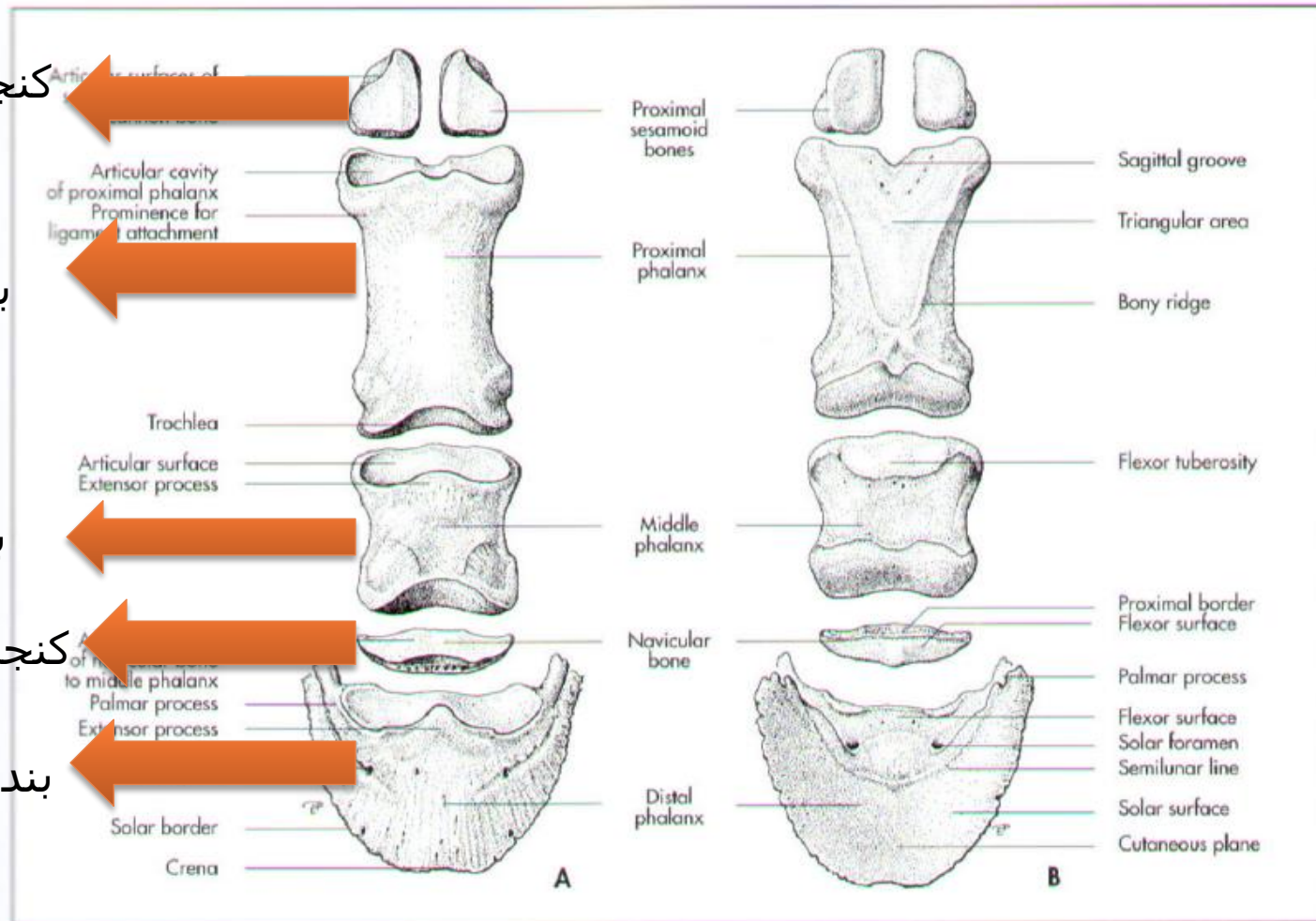
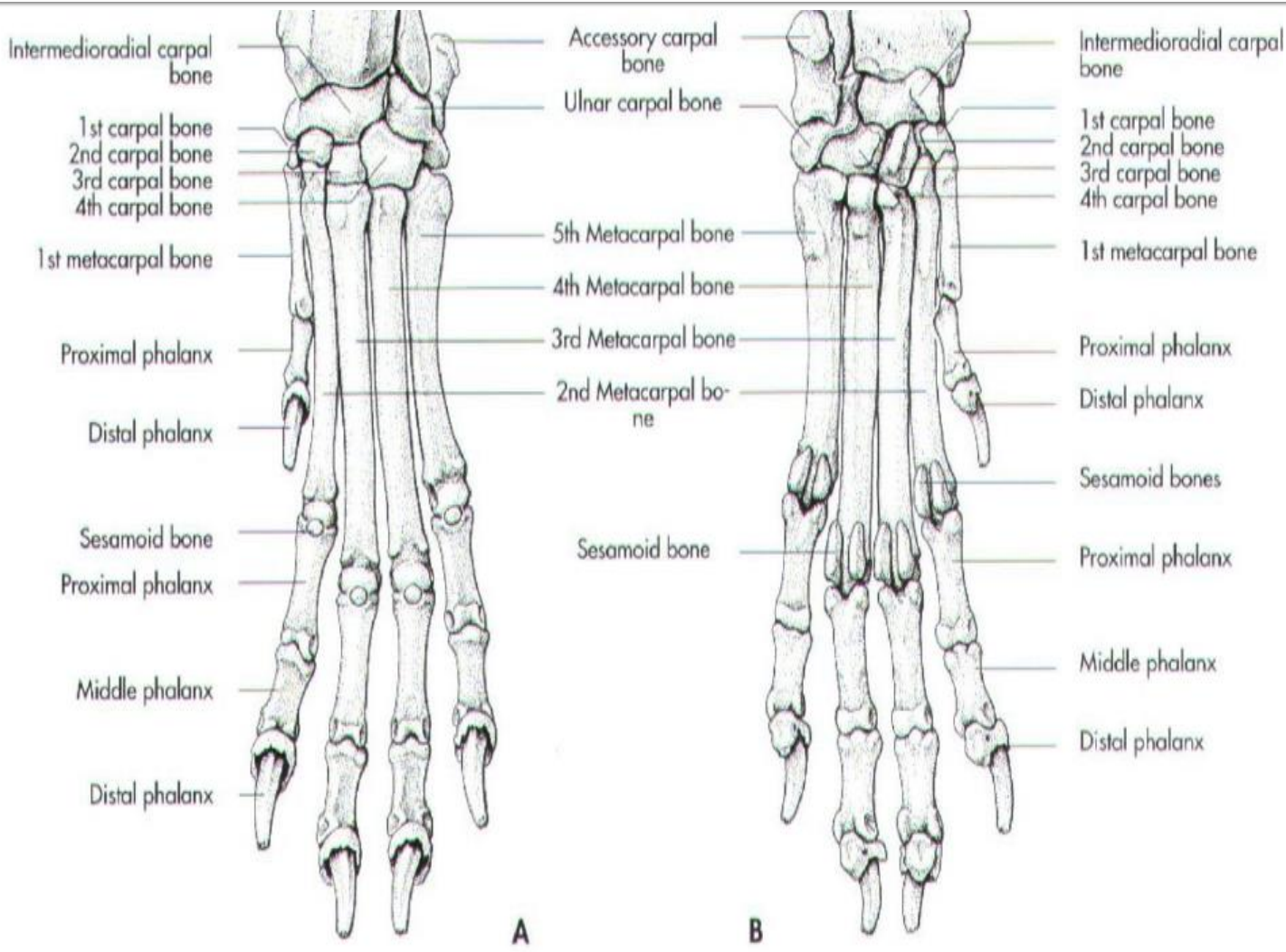


Fig. 3-21. Left digital skeleton of the horse (schematic, A dorsal and B palmar aspect).



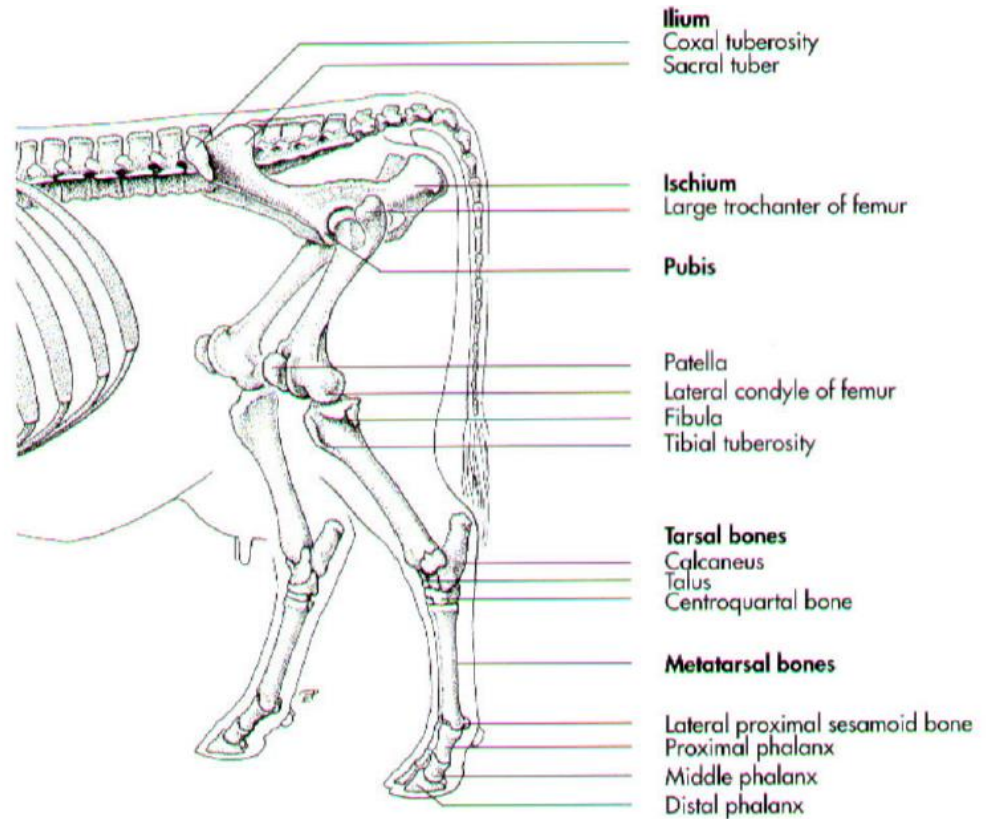
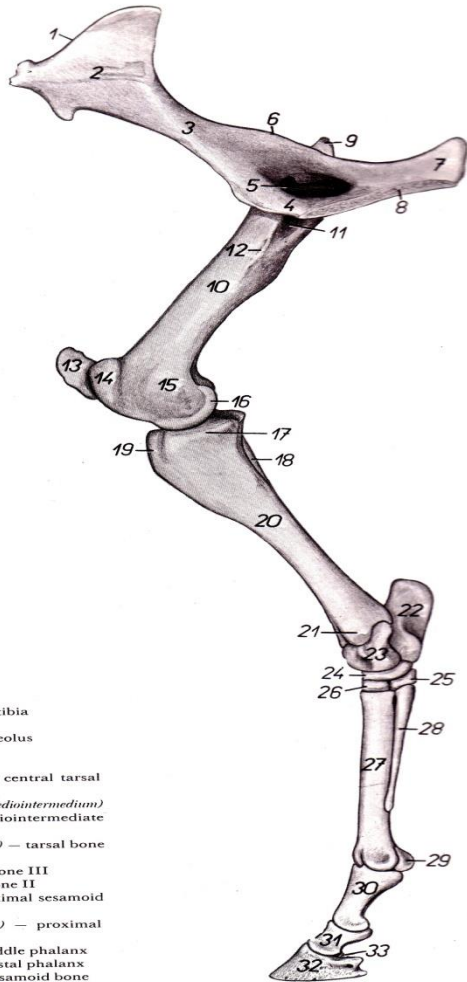
استخوان های اندام حرکتی خلفی

Hind limb bones

- 1- pelvic girdle : کمر بند لگنی
استخوان خاجی Sacrum - استخوان لگن Os coxarum
- 2- Thigh : ران
استخوان ران Femur
- 3- Leg (crus) : ساق پا
درشت نی و نازک نی Tibia and fibula
- 4- Pes : پا
مچ پا ، قلم پا ، انگشتان Tarsus- Metatarsus- Digits

استخوان های اندام حرکتی خلفی

Hind limb bones

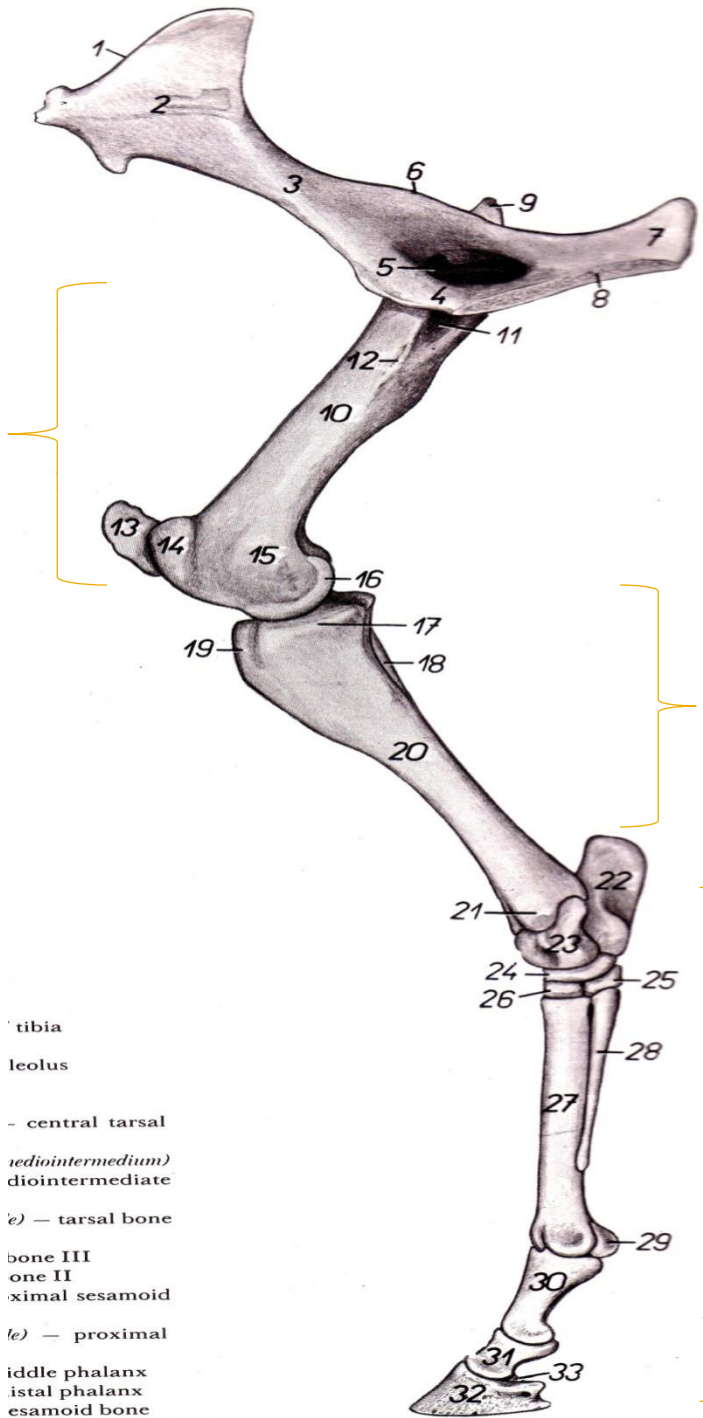


Os coxae

Thigh (femur)

Leg(crus)

Pes



- tibia
- leolus
- central tarsal
- (radiointermedium)
- diintermediate
- e) - tarsal bone
- bone III
- one II
- aximal sesamoid
- e) - proximal
- iddle phalanx
- istal phalanx
- esamoid bone

Hip bone or os coxarum

استخوان لگن

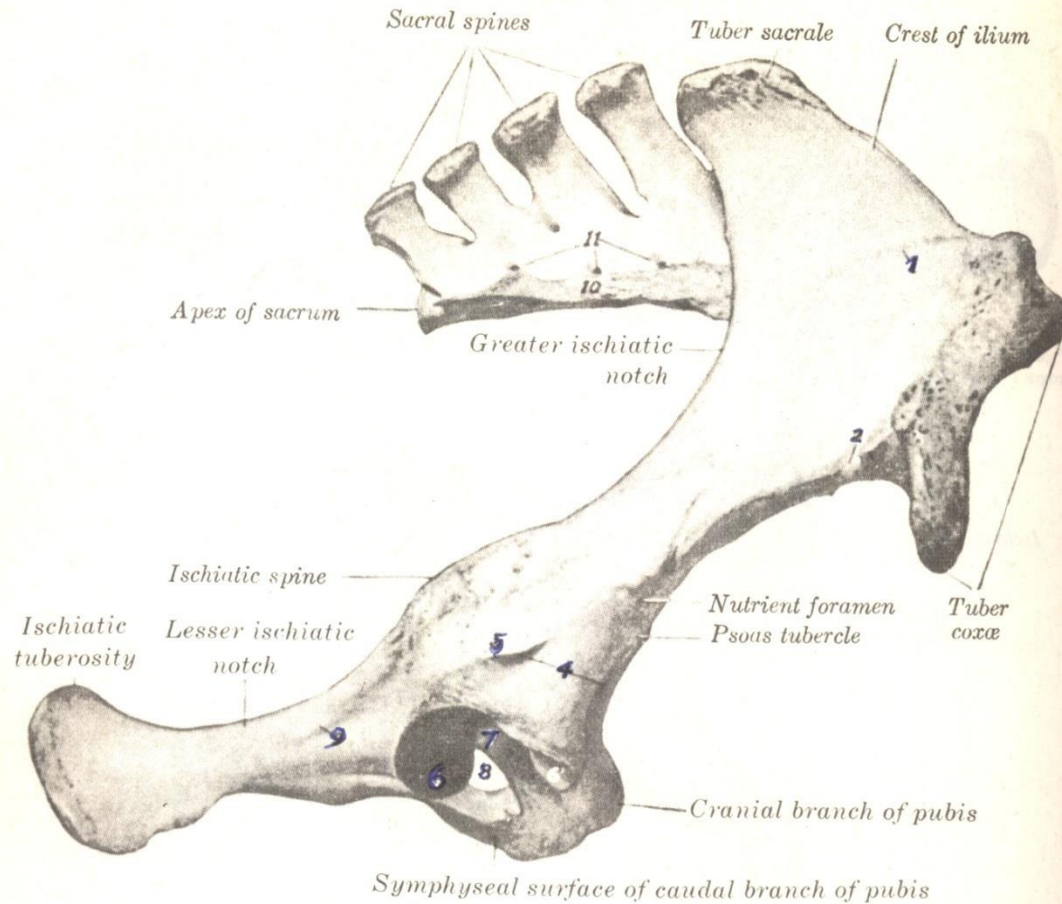
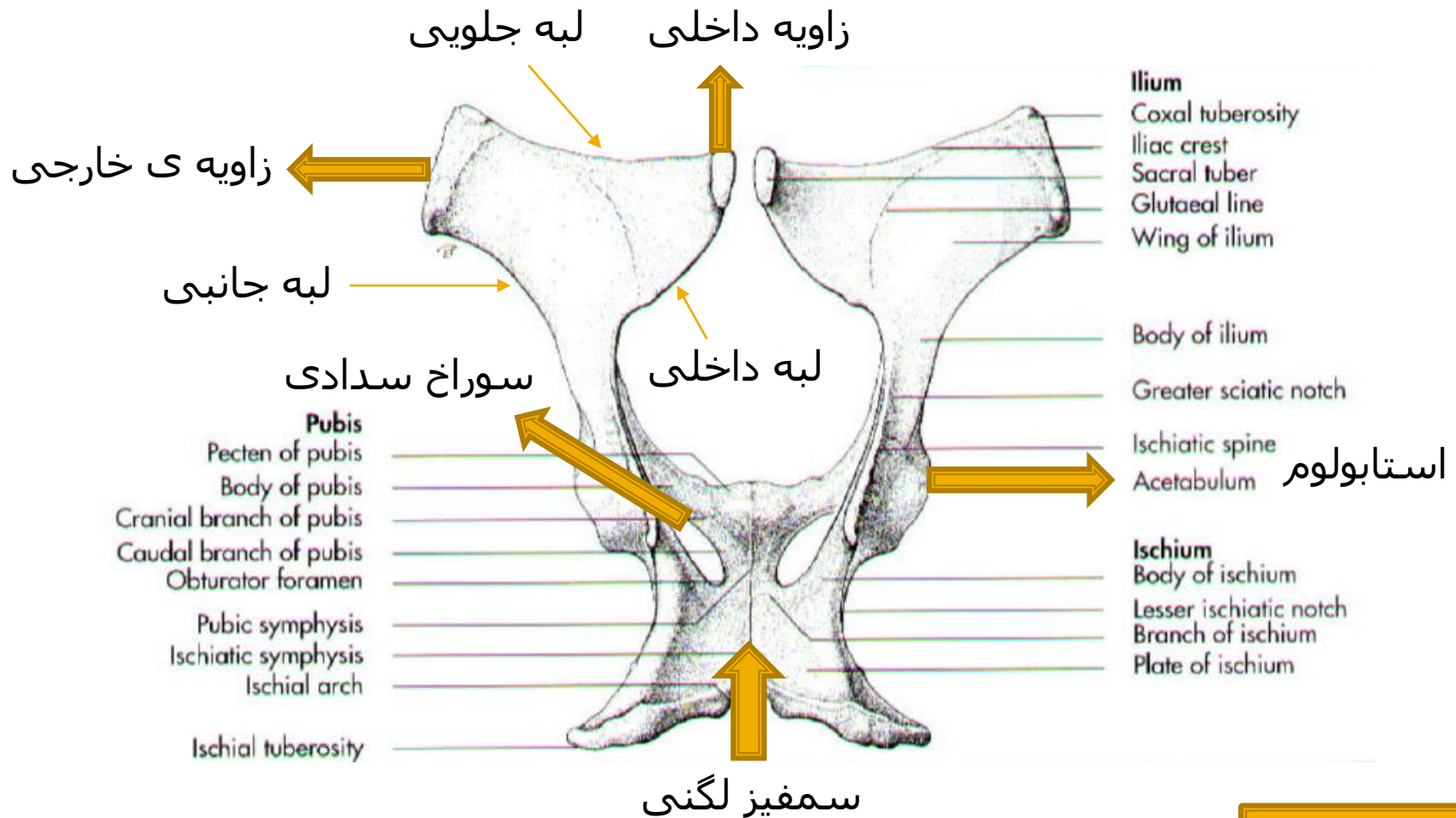


FIGURE 15-72. Right os coxae and sacrum of horse; right lateral view.

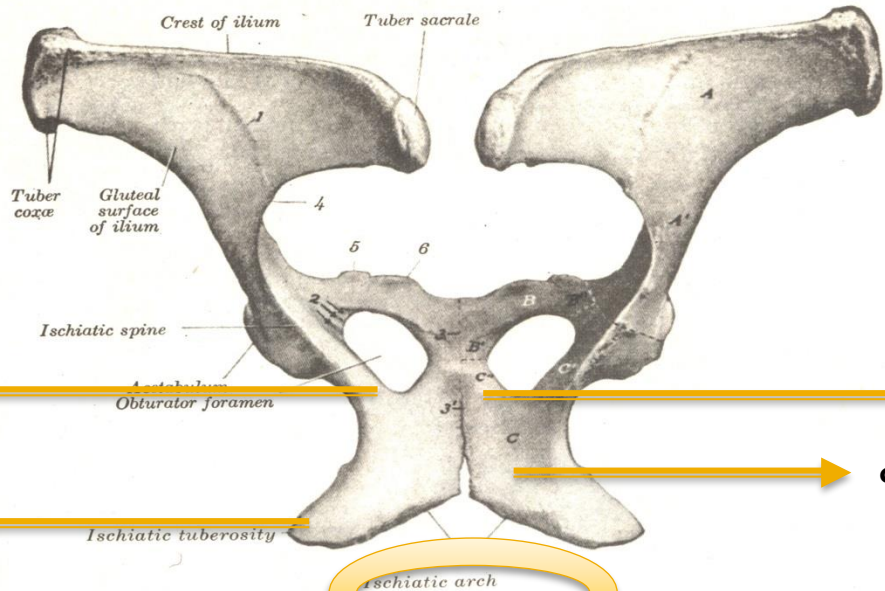
1, Gluteal line; 2, impression of iliolumbar a.; 3, impression of iliocofemoral a.; 4, depressions for attachments of tendons of origin of rectus femoris and capsularis mm. are attached; 5, crest to which lateral tendon of rectus femoris and capsularis mm. are attached; 6, 6', articular surface of acetabulum (*facies lunata*); 7, acetabular fossa; 8, obturator foramen; 9, line for attachment of gemellus m.; 10, lateral part of sacrum; 11, dorsal sacral foramina.

Ilium

ایلیوم یا خاصره



نمای پشتی
لگن در اسب



بدنه

شاخه

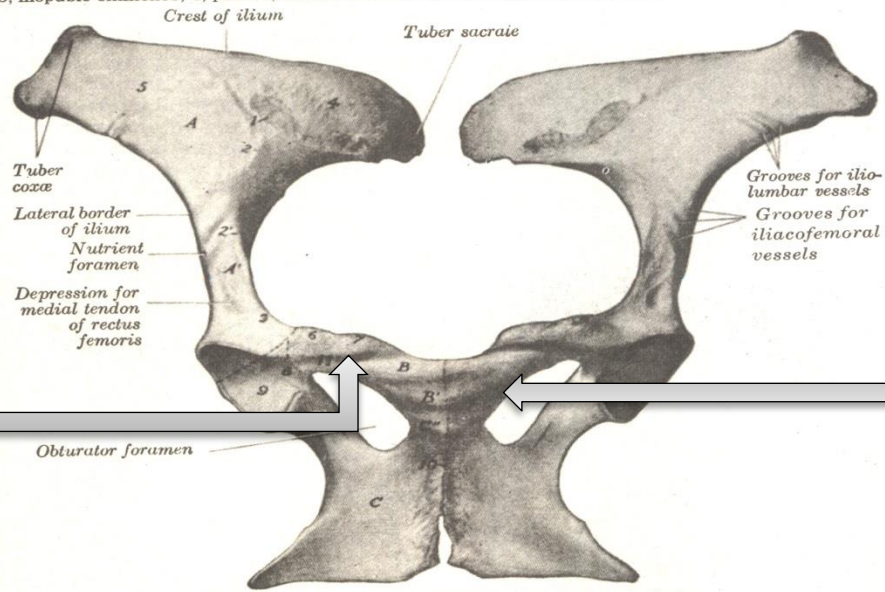
صفحه

برجستگی ورکی

فوس ورکی

FIGURE 15-70. Ossa coxarum of horse; dorsal view.

A, Wing; A', body of ilium; B, cranial (acetabular) and B', caudal (symphyseal) branch of pubis; B'', body of pubis; C, tabula; C', body (formerly acetabular branch of ilium); C'' (symphyseal) branch of ischium; 1, gluteal line; 2, grooves for obturator n. and vessels; 3, pubic symphysis; 3', ischiatic symphysis; 3 + 3', forms the pelvic symphysis; 4, greater ischiatic notch; 5, iliopubic eminence; 6, pubic tubercle. Dotted lines indicate primitive separation of three bones.



Cranial ramus
Of pubic
شاخه جلویی

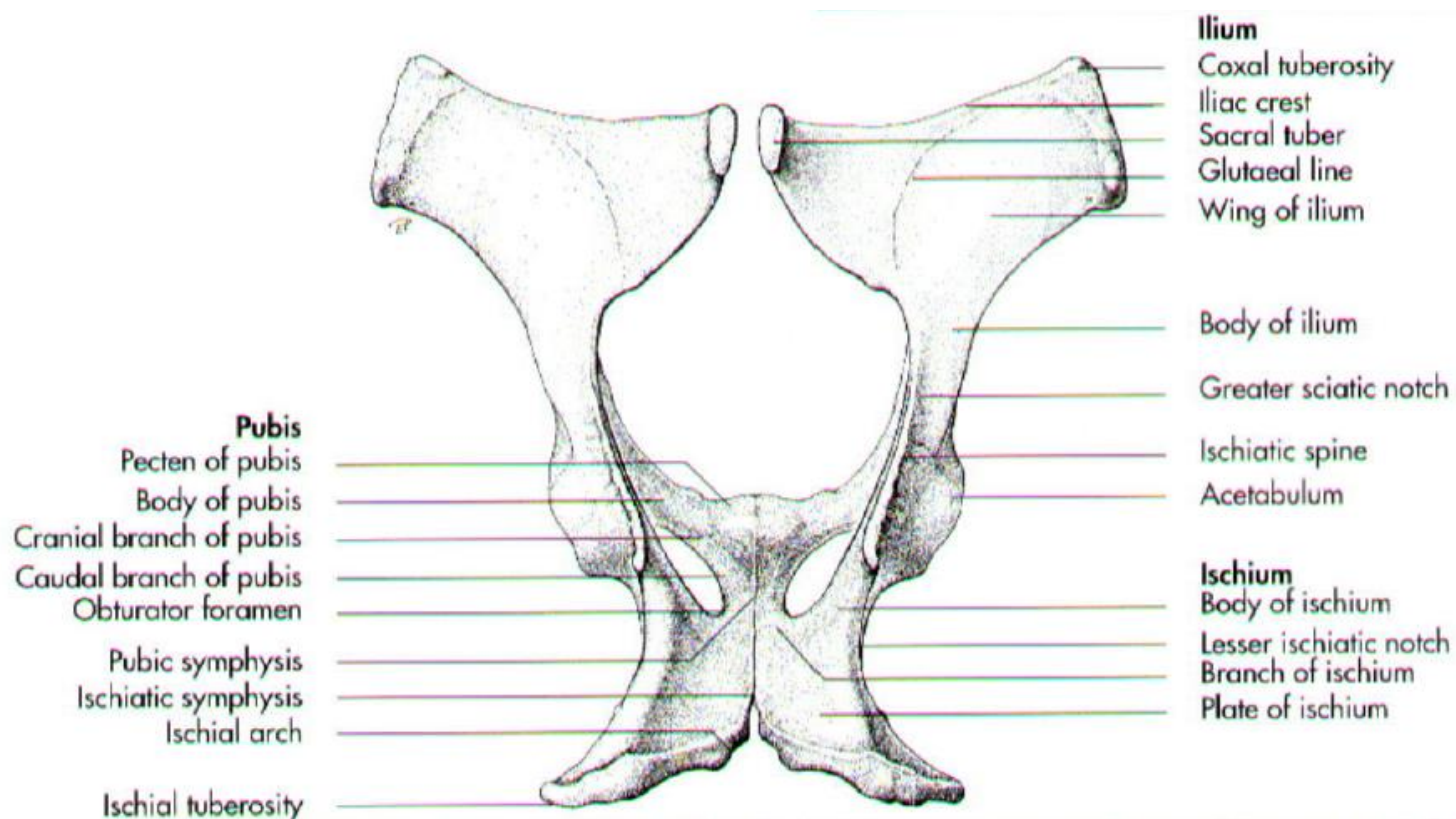
Caudal ramus or
Of pubic
شاخه عقبی

FIGURE 15-71. Ossa coxarum of mare; ventral view.

A, Wing; A', body of ilium; B, cranial (acetabular) branch, B', caudal (symphyseal) branch, of pubis; C, tabula; C', body (formerly acetabular branch, shaft), C'' (symphyseal) branch of ischium; 1, auricular surface; 2 + 3, arcuate (iliopectineal) line; 2', psoas tubercle; 4, iliac tuberosity; 5, iliac part of acetabulum (facies lunata); 6, iliopubic eminence; 7, pubic tubercle; 8, acetabular fossa; 9, articular surface of acetabulum (facies lunata); 10, pelvic symphysis; 11, pubic groove. Dotted lines indicate primitive division of os coxae.

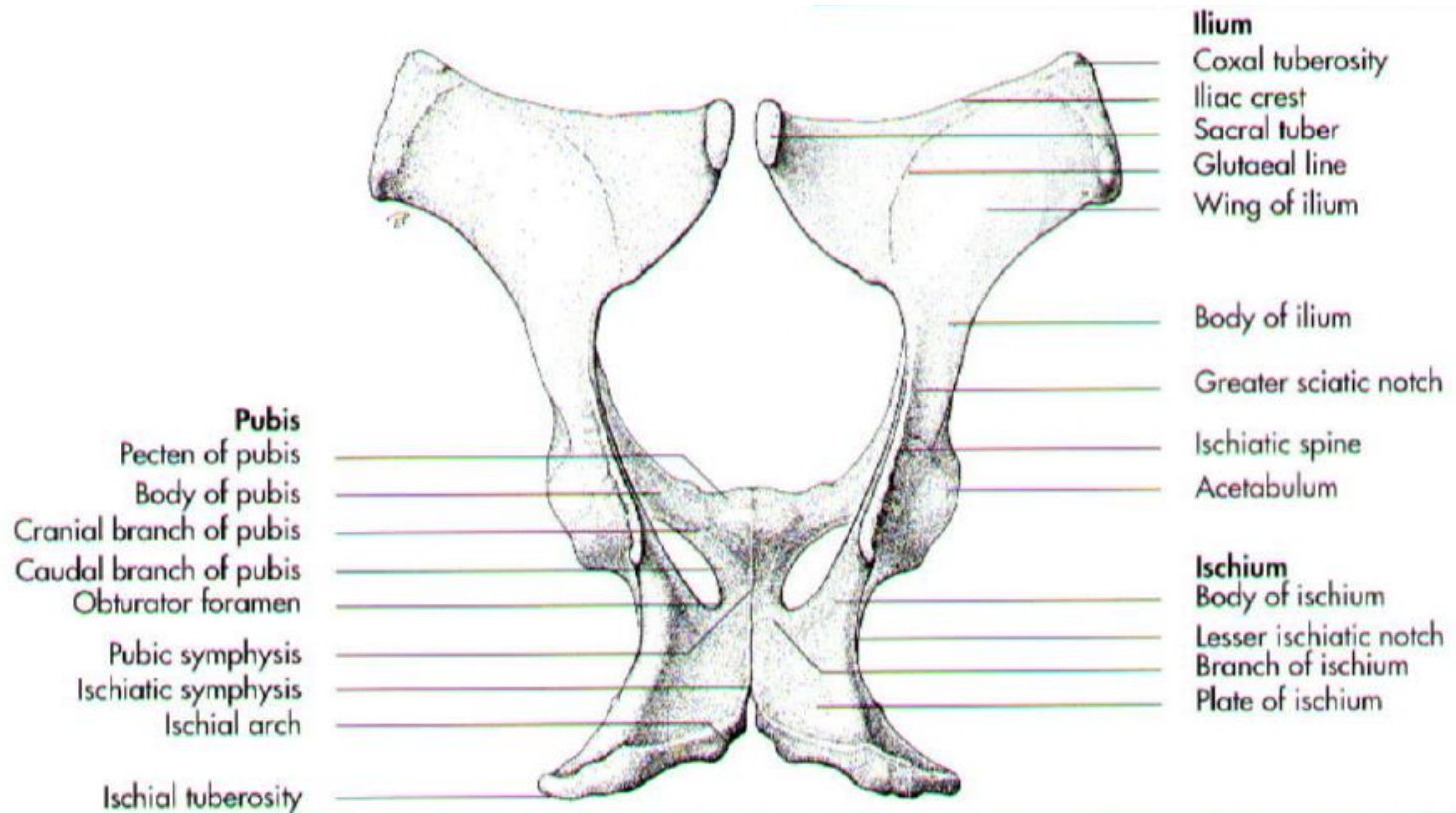
استخوان شرمگاهی

Pubic



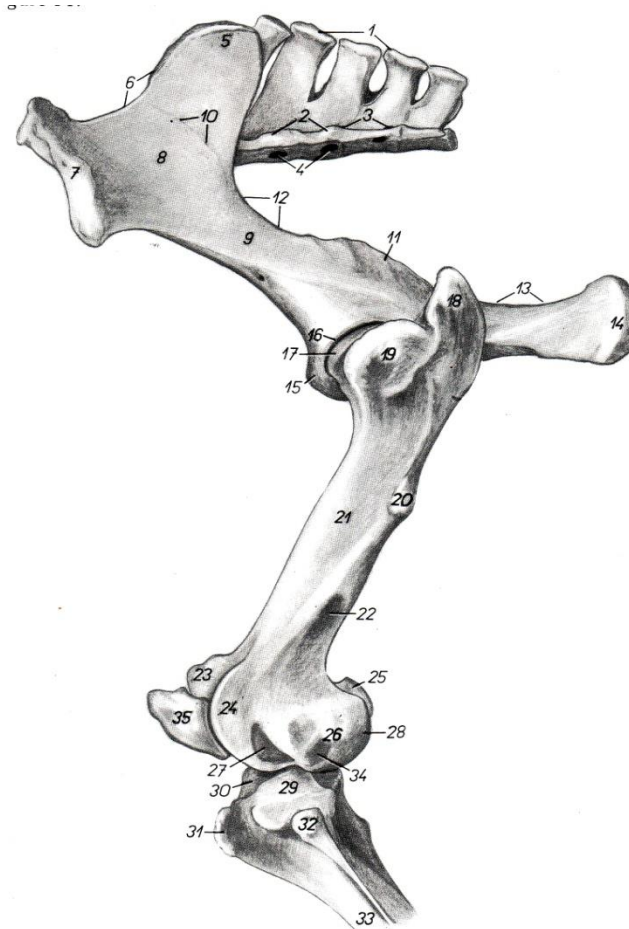
Ischium

استخوان نشیمن گاهی



Femur

استخوان ران



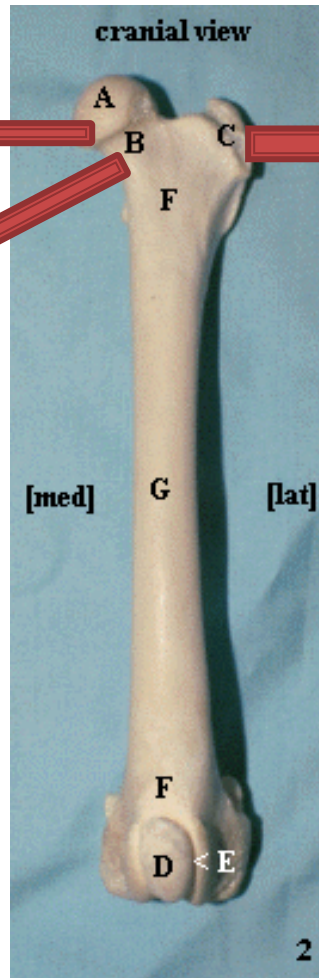

سر استخوان ران



تروکانتر بزرگ



گردن

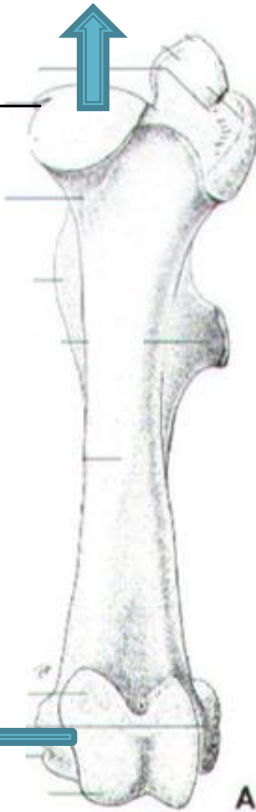


استخوان ران در تک سم

نمای جلویی
سر

Fovea capitis

قرقره

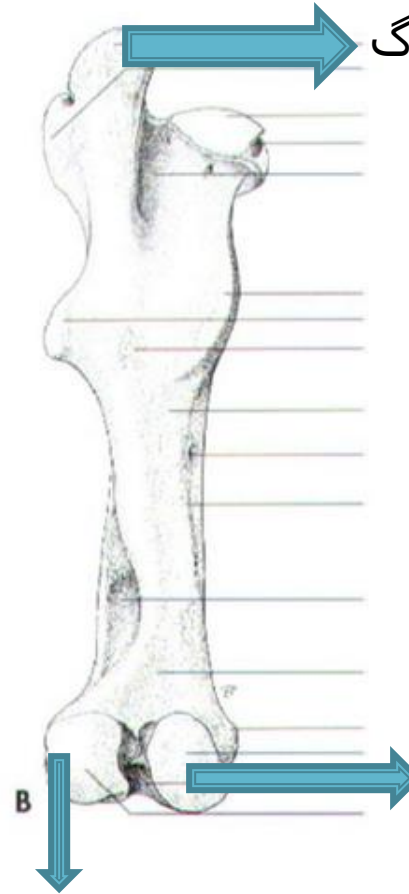


نمای عقبی

تروکانتر بزرگ

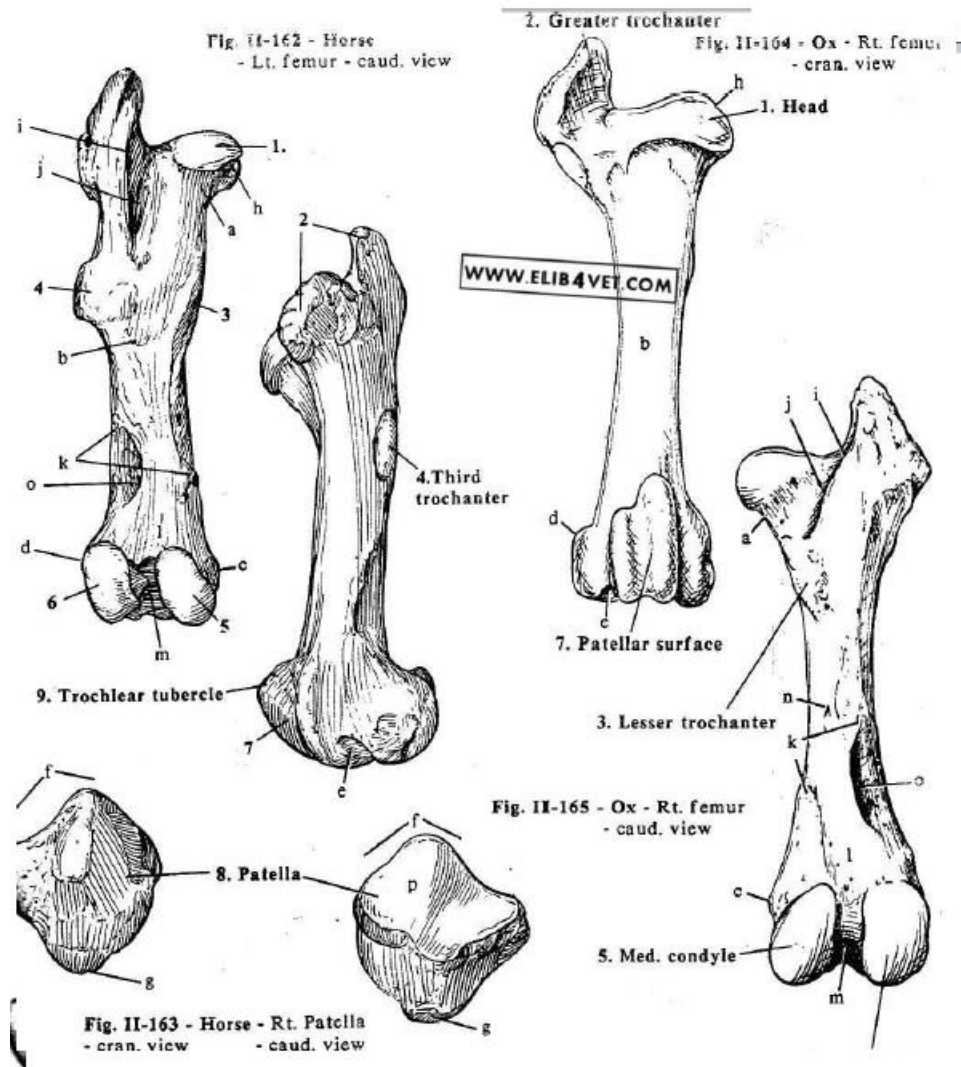
کندیدل جانبی

کندیدل داخلی



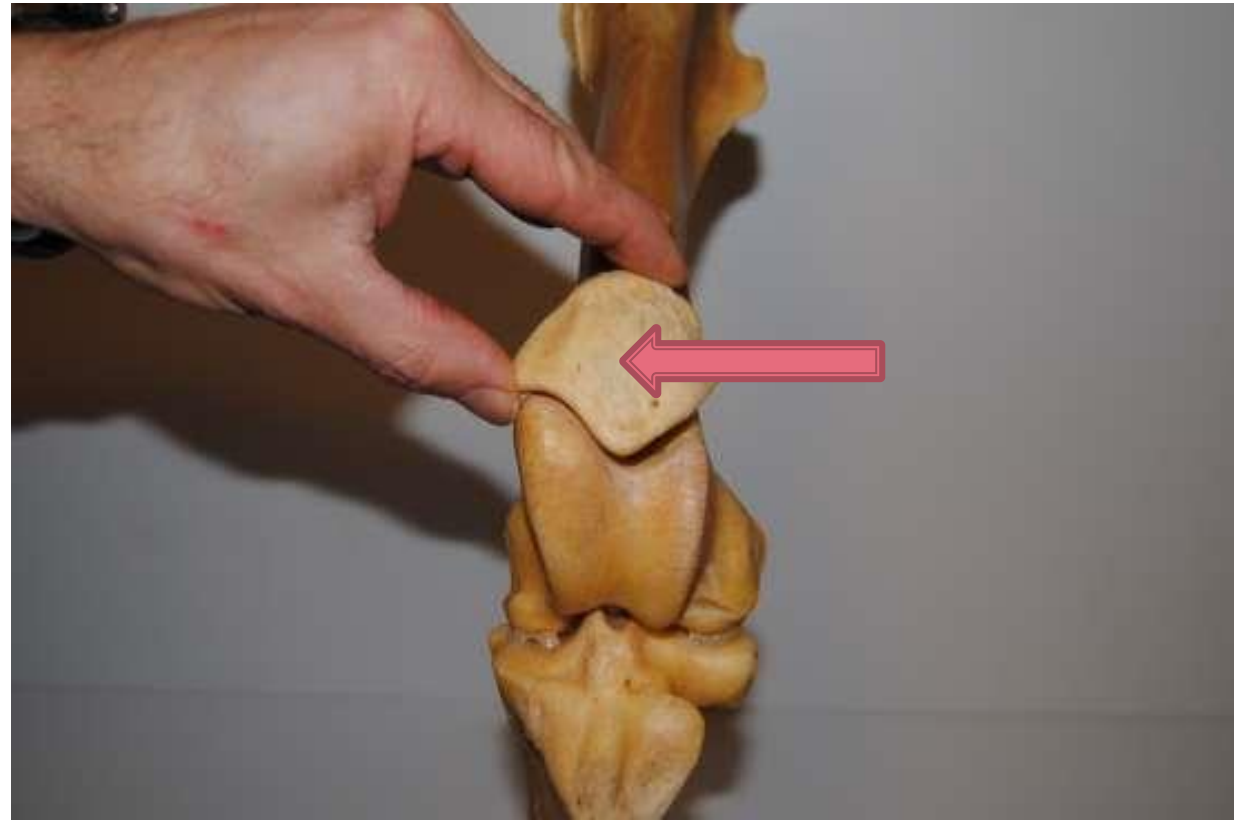
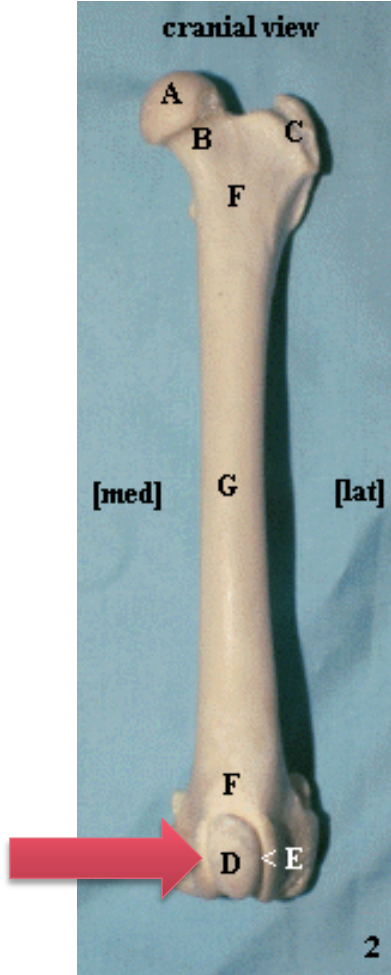
استخوان کشکک

Patella



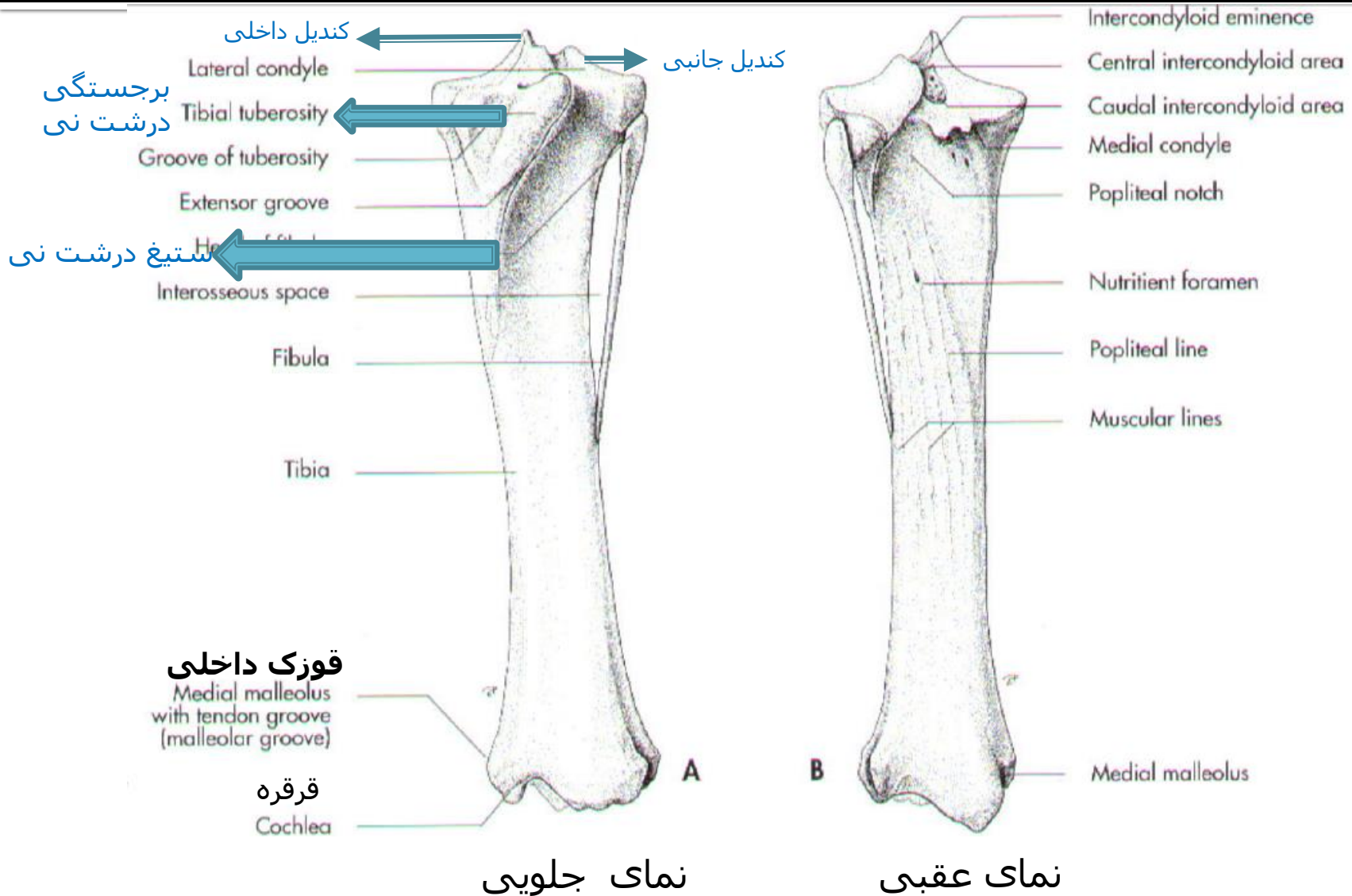
Patella

استخوان کشکک



Tibia & Fibula

درشت نی و نازک نی



TIBIA & FIBULA

Pelvic limb

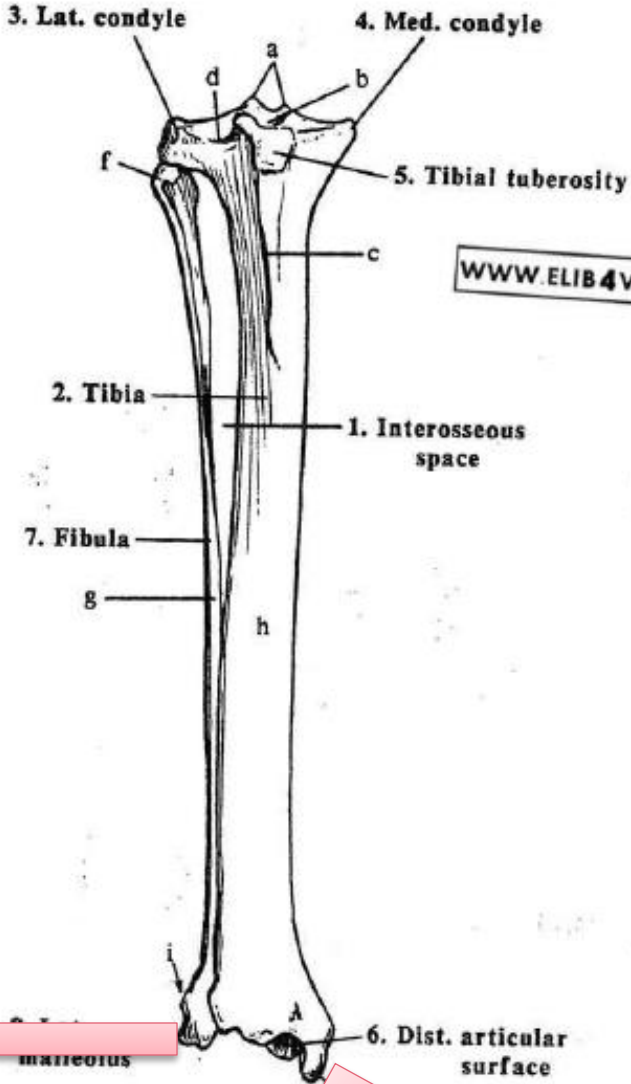
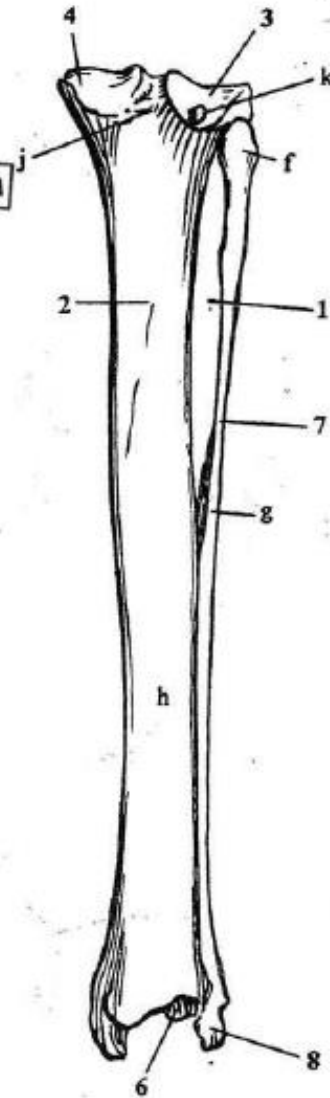


Fig. II-166 - Dog - Rt. tibia & fibula - cran. view

Fig. II-167 - Dog - Rt. tibia - caud. view



قوزک داخلی

قوزک جانبی

Tarsal bones

مچ پا

